



Ashish Shah

Daljit S Gill, Christopher Tredwin and Farhad B Naini

# Diagnosis and Management of Supernumerary Teeth

**Abstract:** Supernumerary teeth can present in various forms and in any region of the mandible or maxilla, but have a predisposition for the anterior maxilla. They can cause a variety of complications in the developing dentition. This article reviews the epidemiology, clinical features, diagnosis and options for the management of supernumerary teeth.

**Clinical Relevance:** Early diagnosis and appropriate management can minimize the potential complications caused by supernumerary teeth. Dental practitioners should be aware of their clinical signs and the treatment options.

**Dent Update 2008; 35: 510-520**

Supernumerary teeth are defined as those in excess when compared to the normal series. Their reported prevalence ranges between 0.3–0.8% in the primary dentition and 0.1–3.8% in the permanent dentition.<sup>1-3</sup> Males are affected approximately twice as often as females. Methodology for detection and variation in the populations studied may account for the range of prevalence

reported.<sup>4</sup> Supernumeraries in the primary dentition may be under-reported. Spacing often present in the primary dentition may allow supernumerary teeth to erupt into reasonable alignment and remain unnoticed by parents. These children may have an initial dental examination following exfoliation of deciduous supernumerary teeth.<sup>4</sup> The results of some major prevalence studies on supernumerary teeth are summarized in Table 1.

Supernumerary teeth can occur as singles, multiples, unilaterally or bilaterally and in the maxilla, the mandible or both.<sup>1</sup> Cases involving one or two supernumerary teeth most commonly affect the anterior maxilla, followed by the mandibular premolar region. There are differences in the reported relative frequencies of supernumerary teeth in other regions.<sup>1</sup> Cases involving multiple supernumeraries (more than five) tend to involve the mandibular premolar region.<sup>4</sup> When investigating non-syndrome multiple supernumerary teeth, Yusuf<sup>2</sup> found 60.9% of the total sample to occur in the mandible and 44.8% in the mandibular premolar region.

Supernumerary teeth are estimated to occur in the maxilla 8.2 to 10 times more frequently than the mandible,<sup>2,3,5</sup> and most commonly affect

the premaxilla.<sup>1</sup> Additionally, there is a significant association between supernumerary teeth and invaginated teeth (teeth with an exaggerated cingulum pit).<sup>6</sup> These findings may be explained by the fact that the embryological development of the premaxilla differs from that of the remaining maxilla. Therefore, there can be deviations in the premaxillary region that do not occur in the remaining maxilla.<sup>7</sup> These deviations may lead to the formation of supernumerary teeth and other anomalies, including invaginated teeth.

## Aetiology

The aetiology of supernumerary teeth is not completely understood. Both genetic and environmental factors have been considered.<sup>8</sup> Several theories have been suggested to explain their occurrence:

## Atavism

It was originally suggested that supernumerary teeth were the result of phylogenetic reversion to extinct primates with three pairs of incisors. This theory has been largely discounted.<sup>9</sup>

## Dichotomy theory

This stated that the tooth bud

**Ashish Shah**, BDS, MFDS RCS(Eng), Specialist Registrar in Orthodontics, Royal Berkshire Hospital (Reading) and Wexham Park Hospital (Slough), **Daljit S Gill**, BDS(Hons), MSc, BSc(Hons), FDS(Orth) RCS(Eng), MOrth, FDS RCS(Eng), Consultant Orthodontist/Honorary Senior Lecturer, Eastman Dental Hospital (UCLH NHS Foundation Trust) and UCL Eastman Dental Institute, Honorary Consultant, Great Ormond Street Hospital, **Christopher Tredwin**, BDS(Hons), BSc(Hons), MSc, MFDS RCS(Eng), FDS(Rest Dent) RCS, FHEA, Clinical Lecturer in Fixed and Removable Prosthodontics, UCL Eastman Dental Institute and **Farhad B Naini**, BDS, FDS RCS, MSc, MOrth RCS, FDSOrth RCS, Consultant Orthodontist, St George's Hospital and Kingston Hospital, London, UK.

Authors	Sample size	Country of study	Age of subjects	Method of detection of supernumeraries	Reported prevalence of supernumeraries	Male: Female ratio
Gabris <i>et al</i> (2006) <sup>28</sup>	2,219 patients	Hungary	6–18 years	Radiographs	1.53%	1.4:1
Tyrologou <i>et al</i> (2005) <sup>29</sup>	97 children with diagnosed mesiodens	Sweden	3–15 years	Clinical examination and radiographs	–	2:1
Rajab and Hamdan (2002) <sup>1</sup>	152 children with diagnosed supernumerary teeth	Jordan	Range from 5–15 years	Clinical examination and radiographs	–	2.2:1
Liu (1995) <sup>10</sup>	112 children with a diagnosis of supernumerary teeth in the premaxillary regions	Taiwan	Range from 4–14 years; mean age 8 years 5 months	Clinical examination and radiographs	–	2.8:1
von Arx (1992) <sup>11</sup>	90 patients with anterior maxillary supernumerary teeth	Switzerland	Age range predominantly 6–10 years	Clinical examination and radiographs	–	2.6:1
Bodin <i>et al</i> (1978) <sup>13</sup>	21,609 patients	Sweden	Not specified	Not specified	1.6%	1.7:1
Brook (1974) <sup>30</sup>	1,331 children	Britain	11–14 years	Clinical examination and radiographs	2.1%	1.4:1
Stafne (1932) <sup>3</sup>	48,550 patients	USA	Average age approximately 40 years	Radiographs	0.91%	–

**Table 1:** Summary of prevalence studies on supernumerary teeth.

splits into two equal or different-sized parts, resulting in the formation of two teeth of equal size, or one normal and one dysmorphic tooth, respectively.<sup>1</sup> However, this theory has been discounted.<sup>9</sup>

#### Dental lamina hyperactivity theory

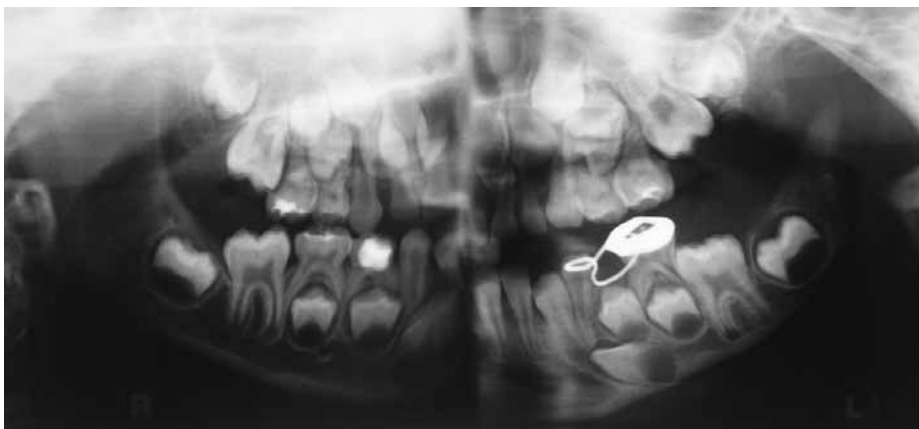
This involves localized, independent, conditioned hyperactivity of the dental lamina.<sup>1</sup> According to this

theory, a supplemental form would develop from the lingual extension of an accessory tooth bud, whereas a rudimentary form would develop from the proliferation of epithelial remnants of the dental lamina.<sup>9</sup>

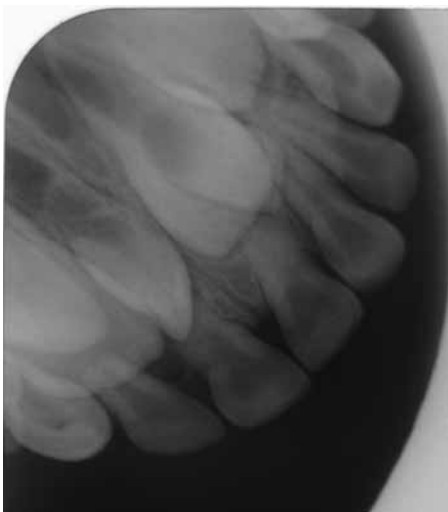
Although all theories are hypothetical because of the inability to obtain sufficient embryological material, most literature supports the dental lamina hyperactivity theory.<sup>9</sup>

#### Genetic factors

These are considered important in the occurrence of supernumerary teeth. Many cases have been reported of recurrence within the same family.<sup>1</sup> A sex-linked inheritance has been suggested by the observation that males are affected approximately twice as often as females.<sup>1,9</sup>



**Figure 1.** A dental panoramic tomograph showing the presence of a supplemental tooth.



**Figure 2.** An upper anterior occlusal radiograph also showing the presence of a supplemental tooth for the same patient as in Figure 1.

### Classification of supernumerary teeth

Supernumeraries are classified according to morphology or location.

#### Classification based on morphology

##### Conical

Conical-shaped supernumerary teeth are the most common.<sup>1</sup> They usually present with conical or triangular-shaped crowns and complete root formation. They are found most often as isolated single cases and are usually located between the maxillary central incisors (mesiodens).<sup>9</sup> However, they can also occur as bilateral (mesiodentes) structures in the premaxilla.<sup>9</sup>

##### Tuberculate

The tuberculate supernumerary has a barrel-shaped appearance and a crown consisting of multiple tubercles.<sup>9</sup> It may be invaginated.<sup>1</sup> Unlike conical supernumerary teeth, which have complete root formation, tuberculate types have either incomplete or absent root formation.<sup>9</sup> They are generally larger than conical supernumerary teeth and are usually found in a palatal position relative to the maxillary incisors.<sup>1,9</sup> Tuberculate supernumeraries are often paired<sup>1</sup> and bilateral supernumerary cases have a predominance of tuberculate-shaped teeth.<sup>9</sup> It has been suggested that tuberculate supernumeraries may represent a third dentition.<sup>9</sup>

##### Supplemental

Supplemental supernumerary teeth resemble their respective normal teeth. They form at the end of a tooth series. The most common supplemental tooth is the permanent maxillary lateral incisor, although supplemental premolars and molars also occur.<sup>1</sup> The majority of supernumerary teeth in the primary dentition are supplemental and rarely remain unerupted.<sup>1,10</sup>

Figures 1 and 2 show a supplemental tooth.

##### Odontomes

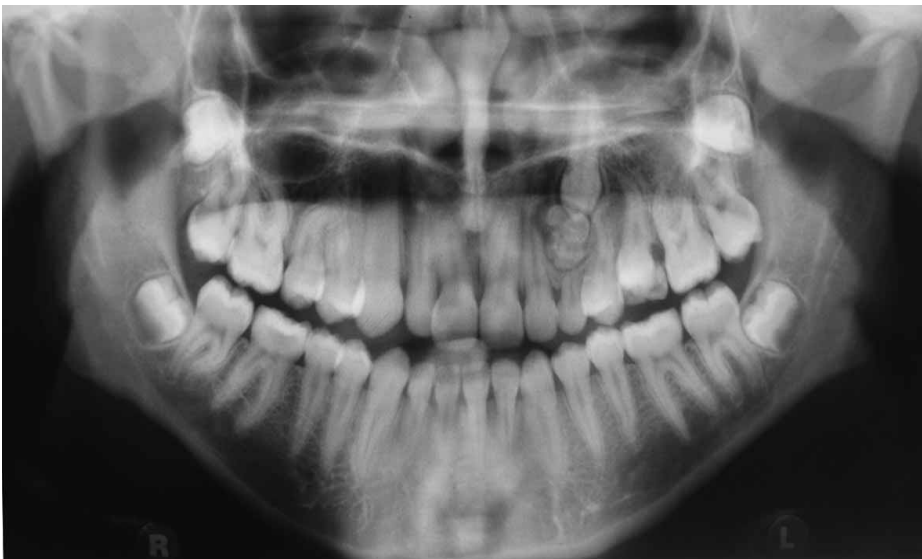
These are hamartomas (benign, disordered overgrowths of mature tissue) comprising all dental tissues and appearing radiographically as well-demarcated, mostly radio-opaque lesions in tooth-bearing areas. There are two different types of odontome: compound and complex. Compound odontomes comprise many separate, small tooth-like structures. A complex odontome (Figure 3) is a single, irregular mass of dental tissue that has no morphological resemblance to a tooth.

The key features of supernumerary teeth are summarized in Table 2.

#### Classification based on location

##### Mesiodens

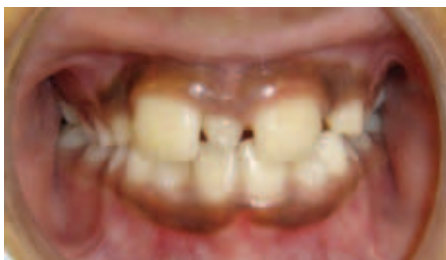Typically, a mesiodens is a conical supernumerary tooth located between the maxillary central incisors.<sup>1</sup> These supernumerary teeth are usually



**Figure 3.** A complex odontome preventing eruption of teeth.

Type of supernumerary	Relative occurrence	Common locations	Typical clinical appearance	Typical radiographic appearance
Conical	75%	Anterior maxilla	Small structures with triangular or conical crown	Appearance of a diminutive tooth with a triangular or conical crown
Tuberculate	12%	Anterior maxilla	Barrel-shaped crown with multiple tubercles	Barrel-shaped crown with incomplete or absent root formation
Supplemental	7%	Any location (most often a permanent maxillary lateral incisor)	Appearance of a normal tooth	Appearance of a normal tooth
Odontome	6%	Anterior maxilla and posterior mandible	Numerous small tooth-like structures or a single, irregular mass	Mixed radio-opaque area surrounded by radiolucent band

**Table 2:** Key features of supernumerary teeth.



**Figure 4.** An erupted mesiodens causing separation of the upper central incisors.

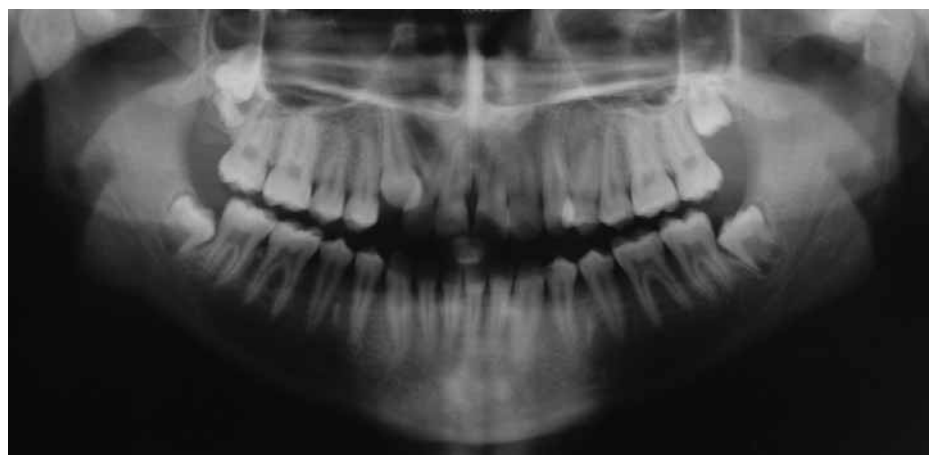located palatal to the permanent incisors, with only a few lying in the line of the arch or labially.<sup>11</sup> The mesiodens is usually small and short, with a triangular or conical crown.<sup>11</sup> Figure 4 shows an example of a mesiodens.

**Paramolar**

A paramolar is a supernumerary molar, usually rudimentary, situated buccally or lingually/palatally to one of the molars or in the interproximal space buccal to the second and third molar. An example is shown in Figure 5.

**Distomolar**

A distomolar is a supernumerary tooth located distal to a third molar and is usually rudimentary. It rarely delays the eruption of associated teeth.



**Figure 5.** A dental panoramic tomograph revealing a paramolar in the 8/ region.

**Parapremolar**

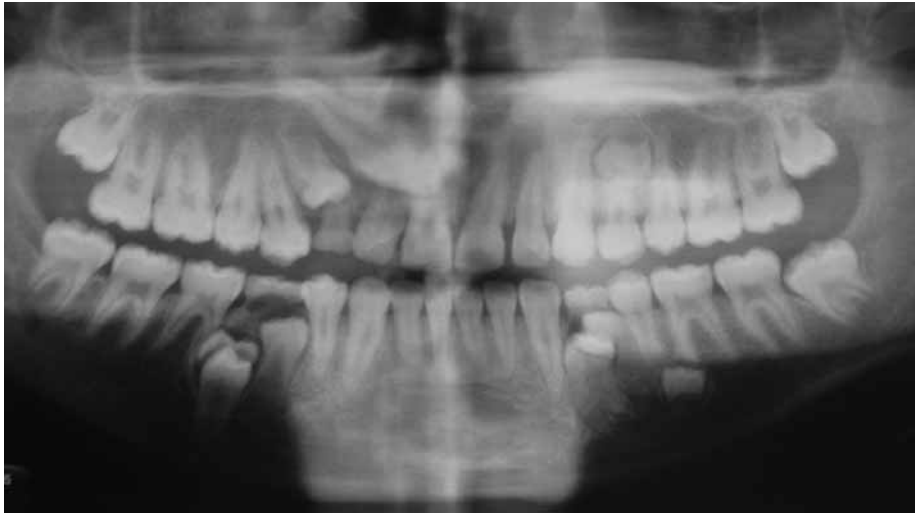This is a supernumerary that forms in the premolar region and resembles a premolar. An example is shown in Figure 6.

**Clinical features of supernumerary teeth**

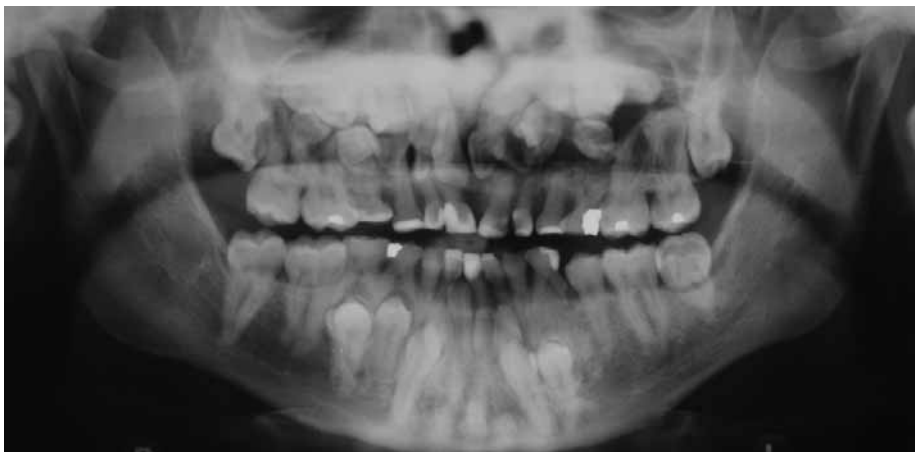
Supernumerary teeth may erupt normally, remain impacted, appear inverted or assume an abnormal path of eruption.<sup>12</sup> Supernumerary teeth with a normal orientation will usually erupt. However, only 13–34% of all permanent supernumerary teeth are erupted, compared with 73% of primary supernumerary teeth.<sup>1</sup>

A supernumerary may be discovered by chance as a radiographic finding with no associated complications. However, if complications arise, they may include the following:

- Prevention or delay of eruption of associated permanent teeth;
- Displacement or rotation of permanent teeth;
- Crowding;
- Incomplete space closure during orthodontic treatment;
- Dilaceration, delayed or abnormal root development of associated permanent teeth;
- Root resorption of adjacent teeth;



**Figure 6.** A dental panoramic tomograph revealing multiple supernumerary premolars.



**Figure 7.** A dental panoramic tomograph revealing multiple supernumeraries in a patient with cleidocranial dysostosis.

- Complications with the supernumerary itself;
- Late-forming supernumerary teeth.

#### **Prevention or delay of eruption of associated permanent teeth<sup>1,13</sup>**

The presence of a supernumerary tooth is the most common cause for failure of eruption of maxillary incisors. Delayed eruption of associated teeth has been reported to occur in 28–60% of Caucasians with supernumerary teeth.<sup>14</sup> Tuberculate supernumeraries are the main cause for failure of eruption of maxillary permanent incisors.<sup>6</sup>

#### **Displacement or rotation of permanent teeth.**

Even in cases where

the unerupted incisors are severely rotated, early removal of the causative supernumerary tooth can result in self-correction and correct alignment.<sup>11</sup> The presence of a supernumerary tooth between the roots of adjacent teeth may prevent root approximation and result in the formation of a diastema.

#### **Crowding**

Erupted supplemental teeth most often cause crowding, although any form of supernumerary can cause this complication. Khalaf *et al*<sup>15</sup> found that, in patients with supernumerary teeth, most of the normal teeth present were larger than in controls. The differences were significant for the mesio-distal dimensions of incisors

and the bucco-lingual dimensions of lower first premolars.<sup>15</sup> Similarly, Brook *et al*<sup>16</sup> found that, in patients with supernumerary maxillary incisor teeth, most of their normal teeth were larger than those of controls. The differences were significant for the mesio-distal crown sizes of the maxillary central and lateral incisors, maxillary canines and mandibular lateral incisors.<sup>16</sup> Dento-alveolar disproportion, as well as the presence of additional teeth, may contribute to crowding in patients with supernumerary teeth.

#### **Incomplete space closure during orthodontic treatment<sup>17</sup>**

The presence of an undiscovered supernumerary tooth, particularly a late forming premolar, may obstruct orthodontic space closure.

#### **Dilaceration, delayed or abnormal root development of associated permanent teeth**

#### **Root resorption of adjacent teeth<sup>1,13,18,19</sup>**

This can lead to loss of tooth vitality.<sup>18</sup>

#### **Complications with the supernumerary itself**

These include cyst formation<sup>1,11,13</sup> and migration into the nasal cavity, maxillary sinus or hard palate. However, histological evidence of cyst formation is only present in 4–9% of unerupted supernumeraries.<sup>9</sup> Additionally, eruption of a supernumerary tooth into the nasal cavity is extremely rare.<sup>9</sup>

#### **Late-forming supernumerary teeth**

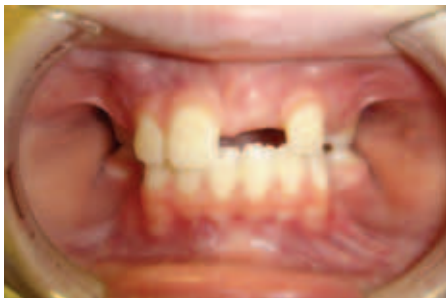Patients with a history of anterior conical or tuberculate supernumerary teeth at an early age have a 24% possibility of developing single or multiple supernumerary premolars.<sup>20</sup>

## **Medical conditions associated with supernumerary teeth**

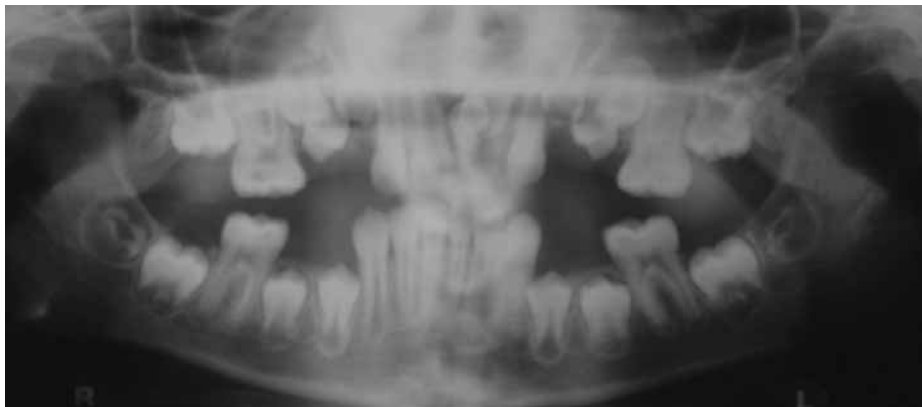Developmental disorders that show an association with multiple supernumerary teeth include:<sup>1,2</sup>

- Cleft lip and palate;
- Cleidocranial dysostosis; and
- Gardner's syndrome.





**Figure 8.** An asymmetric eruption pattern.



**Figure 9.** A dental panoramic tomograph confirming the presence of a supernumerary preventing eruption of 1.

Less common disorders include Fabry Anderson's syndrome, Ehlers-Danlos syndrome, incontinentia pigmenti and Trico-Rhino-Phalangeal syndrome.<sup>21</sup>

#### Cleft lip and palate

Clefts can form in the lip or palate alone, or in both structures. The aetiology is unknown, but there is a genetic component in approximately 40% of cases. Cleft lip occurs in about 1 per 1000 live births, while isolated cleft palate occurs in about 1 per 2000 live births.<sup>22</sup> Teeth in the region of the cleft are typically missing,<sup>22</sup> however, supernumerary teeth can also occur.<sup>1,2</sup>

#### Cleidocranial dysostosis

Cleidocranial dysostosis is a rare syndrome with autosomal dominant inheritance.<sup>21</sup>

The affected gene has been located on chromosome 6p21.<sup>23</sup> The main features include supernumerary teeth, aplasia or hypoplasia of one or both clavicles and other skeletal deformities.<sup>21</sup> The triad of multiple supernumerary teeth, partial or total absence of the clavicles, and open sagittal sutures and fontanelles is considered pathognomonic for cleidocranial dysostosis.<sup>24</sup>

Dental features include multiple supernumerary teeth (Figure 7), multiple crown and root abnormalities, ectopic positions of teeth and failure of eruption.<sup>21</sup> The maxilla is poorly developed while the growth of the mandible is usually normal, resulting in a characteristic skeletal III relationship.<sup>21</sup>

#### Gardner's syndrome

Gardner's syndrome typically

comprises multiple adenomatous polyposis of the large intestine, multiple osteomas of the facial bones, cutaneous epidermoid cysts, desmoid tumours and fibrous hyperplasia of the skin and mesentery.<sup>21</sup> Inheritance is autosomal dominant with complete penetrance and variable expressivity. The affected gene is located on the long arm of chromosome 5. The syndrome represents part of the spectrum of familial colorectal polyposis.<sup>21</sup>

Oral manifestations include multiple odontomes and other supernumerary teeth, impacted teeth and osteomas of the jaws.<sup>21</sup>

### Diagnosis of supernumerary teeth

An unerupted supernumerary tooth may be found by chance during radiographic examination, with no effect on adjacent teeth.<sup>1</sup>

Unilateral persistence of a deciduous incisor, failure of eruption or ectopic eruption of a permanent incisor, a wide diastema, or rotation of erupted permanent incisors should alert the clinician to the possible presence of supernumerary teeth<sup>11</sup> and indicate appropriate radiographic investigation. Figure 8 shows an asymmetric eruption pattern of the maxillary central incisors. Radiographic investigation confirmed the presence of a supernumerary tooth preventing eruption of the upper left central incisor (Figure 9).

The most useful radiographic investigation is the rotational tomograph (OPG), with additional views of the

anterior maxilla and mandible, in the form of occlusal or periapical radiographs. If concerns are present regarding the possibility of root resorption of a permanent tooth caused by a supernumerary tooth, then long-cone periapical radiographs will be required for diagnosis.

In order to localize an unerupted supernumerary or normal tooth, the parallax method is recommended.<sup>25</sup> Parallax is the apparent movement of an object against a background, caused by a change in observer position. This can be achieved with two separate radiographs taken at different angles, but showing the same region. When using this technique, the reference point is usually the root of an adjacent tooth. The image of the tooth that is further away from the x-ray tube head will move in the same direction as the tube head; the image of the tooth that is closer will move in the opposite direction.

In addition, cone-beam computed tomography has recently been used to evaluate supernumerary teeth.<sup>26</sup> This technique yields detailed three-dimensional images of local structures and may prove useful in pre-treatment evaluation of supernumerary teeth and surrounding structures.

Supernumerary premolars commonly occur in several regions of the same mouth, so the finding of one indicates radiographic examination of the other premolar regions.<sup>20</sup>

### Management

The first stage of management

is the localization and identification of complications associated with supernumeraries. Teeth can be localized using the vertical or horizontal parallax technique. A periapical radiograph taken using the paralleling technique gives the most detailed assessment compared to other radiographic views.

If teeth are causing no complications and are not likely to interfere with orthodontic tooth movement (ie if they lie beyond the dental apices) they can be monitored with yearly radiographic review. The patient should be warned of complications, such as cystic change and migration with damage to nearby roots. If the patient does not wish to risk such complications, it is acceptable to remove supernumerary teeth. If they are associated with the roots of permanent teeth, it may be sensible to await full root development before surgical extraction to minimize the chances of root damage. Root development of the maxillary incisors should be complete by the age of ten years.

If supernumerary teeth are associated with complications, it is usual to extract such teeth, which usually involves a surgical procedure. Early extraction of supernumeraries, causing incisor impaction, may have the benefit of minimizing loss of eruptive potential, space loss and centreline displacement. Even in cases where the unerupted incisors are severely rotated, early removal of the causative supernumerary tooth can result in self-correction and correct alignment.<sup>9</sup> The greatest concern with early removal is the risk of affecting the formation of adjacent roots.<sup>9</sup> Additionally, a young child may be unable to tolerate such a procedure and may develop a dental phobia. However, delayed eruption of maxillary central incisors can result in mesial movement of the lateral incisors, space loss and diminished development of dento-alveolar height.<sup>1</sup> Furthermore, in situations where a supernumerary tooth is preventing the eruption of an incisor, the eruptive potential of the incisor may be lost if intervention is delayed.

Following removal of supernumerary teeth, the time taken for the unerupted tooth to erupt can vary between six months and three years.<sup>1</sup> Up to 91% of impacted permanent incisors erupt within 18 months following removal.<sup>27</sup> Factors

affecting the time taken include the distance the unerupted tooth was displaced, the space available in the dental arch and the stage of root development of the permanent tooth.<sup>1</sup> The patient's age and the availability of space in the dental arch are the two critical factors in determining whether spontaneous eruption occurs following removal of supernumerary teeth.<sup>27</sup>

At the initial operation to remove the supernumerary, attachment of a gold chain to the unerupted tooth gives the option of applying orthodontic traction to the tooth if it does not erupt spontaneously. However, in order to expose the unerupted tooth sufficiently for an attachment to be bonded, a greater amount of supporting bone needs to be removed. Exposure of the unerupted tooth (with or without a bonded attachment) may result in poor gingival aesthetics, with less attached gingivae between the exposed tooth and neighbouring teeth.<sup>14</sup>

If supernumerary teeth are likely to interfere with orthodontic tooth movement, they should be removed prior to the commencement of treatment.

If a supplemental tooth is present and erupted, it may be difficult to determine which is the supplemental and which is the tooth of the normal dental series. In these circumstances, assuming both teeth are healthy, it is logical to extract the tooth most displaced from the line of the arch for the relief of crowding.

Finally, the presence of a supernumerary tooth should alert the clinician to the possibility of the development of late forming supernumerary teeth, especially in the lower premolar region. It has been reported that up to 24% of patients with an anterior maxillary supernumerary may later develop supplemental premolars.

## Conclusion

Supernumeraries are relatively common and can cause a variety of complications. The clinician should recognize signs suggesting the presence of supernumerary teeth, particularly aberrations in the eruptive pattern, and perform the relevant investigations. On diagnosis, each case should be managed appropriately in order to minimize complications to the developing dentition. This may include referral to an orthodontist.

## References

1. Rajab LD, Hamdan MAM. Supernumerary teeth: review of the literature and a survey of 152 cases. *Int J Paediatr Dent* 2002; **12**: 244–254.
2. Yusof WZ. Non-syndrome multiple supernumerary teeth: literature review. *J Can Dent Assoc* 1990; **56**: 147–149.
3. Stafne, EC. Supernumerary teeth. *Dent Cosmos* 1932; **74**: 653–659.
4. Scheiner MA, Sampson WJ. Supernumerary teeth: a review of the literature and four case reports. *Aust Dent J* 1997; **42**: 160–165.
5. Acikoz A, Tunga U, Otan F. Characteristics and prevalence of non-syndrome multiple supernumerary teeth: a retrospective study. *Dentomaxillofac Radiol* 2006; **35**: 185–190.
6. Welbury RR, Duggal MS, Hosey M-T. *Paediatric Dentistry* 3rd edn. Oxford: Oxford University Press, 2005.
7. Hansen L, Kjaer I. A premaxilla with a supernumerary tooth indicating a developmental region with a variety of dental abnormalities: a report of nine cases. *Acta Odontol Scand* 2004; **62**: 30–36.
8. Hall A, Onn A. The development of supernumerary teeth in the mandible in cases with a history of supernumeraries in the pre-maxillary region. *J Orthod* 2006; **33**: 250–255.
9. Primosh RE. Anterior supernumerary teeth – assessment and surgical intervention in children. *Pediatr Dent* 1981; **3**: 204–215.
10. Liu JF. Characteristics of premaxillary supernumerary teeth: a survey of 112 cases. *ASDC J Dent Child* 1995; **62**: 262–265.
11. von Arx T. Anterior maxillary supernumerary teeth: a clinical and radiographic study. *Aust Dent J* 1992; **37**: 189–195.
12. Nazif MM, Ruffalo RC, Zullo T. Impacted supernumerary teeth: a survey of 50 cases. *J Am Dent Assoc* 1983; **106**: 201–204.
13. Bodin I, Julin P, Thomsson M. Hyperdontia. I. Frequency and distribution of supernumerary teeth among 21,609 patients. *Dentomaxillofac Radiol* 1978; **7**: 15–17.
14. Mitchell L, Bennett TG. Supernumerary

teeth causing delayed eruption – a retrospective study. *Br J Orthod* 1992; **19**: 41–46.

15. Khalaf K, Robinson DL, Elcock C, Smith RN, Brook AH. Tooth size in patients with supernumerary teeth and a control group measured by image analysis system. *Arch Oral Biol* 2005; **50**: 243–248.
16. Brook AH, Elcock C, al-Sharood MH, McKeown HF, Khalaf K, Smith RN. Further studies of a model for the etiology of anomalies of tooth number and size in humans. *Connect Tissue Res* 2002; **43**(2-3): 289–295.
17. Shah A, Hirani S. A late-forming mandibular supernumerary: a complication of space closure. *J Orthod* 2007; **34**: 168–172.
18. Zmener O. Root resorption associated with an impacted mesiodens: a surgical and endodontic approach to treatment. *Dent Traumatol* 2006; **22**: 279–282.
19. Sian JS. Root resorption of first permanent molar by a supernumerary premolar. *Dent Update* 1999; **26**: 210–211.
20. Solares R, Romero MI. Supernumerary premolars: a literature review. *Pediatr Dent* 2004; **26**: 450–458.
21. Gorlin RJ, Cohen MM, Stefan Levin L. *Syndromes of the Head and Neck* 3rd edn. Oxford: Oxford University Press, 1990: pp.249–253.
22. Cawson RA, Odell EW. *Essentials of Oral Pathology and Oral Medicine* 6th edn. China: Churchill Livingstone, 2002: pp.28–31.
23. Mundlos S. Cleidocranial dysplasia: clinical and molecular genetics. *J Med Genet* 1999; **36**: 177–182.
24. Tanaka JL, Ono E, Filho EM, Castilho JC, Moraes LC, Moraes ME. Cleidocranial dysplasia: importance of radiographic images in diagnosis of the condition. *J Oral Sci* 2006; **48**: 161–166.
25. Jacobs SG. Radiographic localization of unerupted maxillary anterior teeth using the vertical tube shift technique: the history and application of the method with some case reports. *Am J Orthod Dentofacial Orthop* 1999; **116**: 415–423.
26. Liu DG, Zhang WL, Zhang ZY, Wu YT, Ma XC. Three-dimensional evaluations of supernumerary teeth using cone-beam computed tomography for 487 cases. *Oral Surg Oral Med Oral Pathol Oral Radiol Endod* 2007; **103**: 403–411.
27. Leyland L, Batra P, Wong F, Llewelyn R. A retrospective evaluation of the eruption of impacted permanent incisors after extraction of supernumerary teeth. *J Clin Pediatr Dent* 2006; **30**: 225–231.
28. Gabris K, Fabian G, Kaan M, Rozsa N, Tarjan I. Prevalence of hypodontia and hyperdontia in paedodontic and orthodontic patients in Budapest. *Community Dent Health* 2006; **23**: 80–82.
29. Tyrologou S, Koch G, Kurol J. Location, complications and treatment of mesiodentes – a retrospective study in children. *Swed Dent J* 2005; **29**: 1–9.
30. Brook AH. Dental anomalies of number, form and size: their prevalence in British schoolchildren. *J Int Assoc Dent Child* 1974; **5**: 37–53.

## Hi-Di® Wins Again

I wonder why?

### Diamond Bur Market Share Data

Year on Year Growth\*

**Hi-Di® 38.7%**  
+1.4% since 2006

**Private Label 34.4%**  
-0.5% since 2006

## Hi-Di® DIAMOND BURS



- Multi-layers
- Precision-engineered shank
- 100% inspection after production
- The UK's Number 1 Bur\*

Hi-Di® - Do you know how good it is?  
Call for a consultation with our experienced staff

For more information on Ash Instruments®, please call our freephone number or email us:

 +44 (0)800 072 3313

 enquiry@dentsply-gb.com

www.ash-instruments.co.uk **www.dentsply.com**

For better dentistry

**DENTSPLY**



G1425

\*SDM data Q4 2007