American Journal of ORTHODONTICS

Volume 70, *Number* 5, **NOVEMBER, 1976**

ORIGINAL ARTICLES

Comprehensive care of cleft lip and palate children at Zürich University: A preliminary report

M. Hotz, M.D., D.M.D.,* and W. Gnoinski, D.M.D.*
Zürich, Switzerland

The controversy for or against early orthopedic treatment of cleft lip and palate patients still continues. American authors especially[1, 19, 21] "vigorously" deny its usefulness and are trying to prove that their cases, results of "conservative surgery only," provide a "yardstick against early orthopedics." Unfortunately, they generally refer to it in connection with primary bone grafting, the effects of which procedure must be considered separately. Some recent publications advocating early orthopedics[10, 14, 17, 22] state that it has definite advantages as concerns both growth and development and primary surgery.

Evaluation of orthopedic measures is not possible unless based on detailed knowledge of concomitant surgical interventions and their possible effects. It is well known that, even under the same heading, procedures vary considerably from surgeon to surgeon and, even if performed by the same operator, their effects may differ from case to case because of anatomic and functional variability. Differentiated long-term surveys of a sufficient number of cases similarly treated from birth to adulthood are, apparently, not available to date. Procedures were improved, modified, or abandoned in the course of the years. Thus, the number of really comparable cases dwindles.

In order to obtain a comprehensive evaluation, growth and occlusal and esthetic results ought to be checked in relation to initial anatomic and functional variables and must be connected in parallel with speech proficiency and hearing capacity and/or trouble. Speech, moreover, greatly depends on the patient's IQ and on his psychologic and social attitudes. When one considers the infinite

*Orthodontic Department, Zürich University Dental Institute.

number of individual variables, any set of statistics becomes questionable. Mean values do not even reflect a general picture unless based on a most specific division of cases. At the time of primary surgery, it is virtually impossible to judge the individual basic pattern and to predict environmental influences. Infant cephalometrics as well as sophisticated cast analysis can be useful for longitudinal comparisons, but they have little value in initial treatment planning.

In view of these difficulties and of the very limited number of patients (our center deals with a population of only about 1.5 million), we have to rely largely on principles implied by common sense: Any treatment must be based on the greatest possible care and consideration for tissue development.

Evolution of early orthopedic treatment at the Zürich University Dental Institute

At our clinic, preoperative treatment to align maxillary segments in cases of cleft lip and palate was undertaken in 1957, according to McNeil.[15] On checking the first longitudinal series of models (from 1957 to 1964), it became obvious that forced approximation of segments is inadvisable, even contraindicated, but that delayed surgery permits a considerable growth potential to become manifest. Thus, in our opinion, the *primary objective of early orthopedics* is not to facilitate surgery, as postulated by McNeil, but to *take advantage of intrinsic developmental potentialities.* Consequently, the procedure was greatly modified as a result of growing experience and further simplified through use of compound soft and hard acrylic plates, introduced in 1965.[7]

The technique has not since been modified, except for extraoral traction in bilateral cases, which has now been completely abandoned. Results of preoperative treatment were obviously positive but in former years were regularly impaired by so-called "conventional surgery" performed by pediatric surgeons: a straight Veau cut for the lip at 3 months of age and a slightly modified Veau-Langenbeck procedure for the palate at 2 years of age, with shifting of large pedicled mucoperiosteal flaps supplemented by lateral release incisions and a tamponade.[6] Adverse effects of this technique (maxillary collapse, etc.) varied in extent and gravity according to the severity of the initial state, the surgeon's skill, and the individual growth pattern. The great majority of older patients came up for secondary osteotomies in adulthood and they are largely contributed to the boom of maxillofacial surgery in Zürich.

Being able to induce a change of primary surgery only gradually in the earlier years (1965 to 1970), we attempted postoperative retention in order to prevent collapse.[7] Correct occlusion could mostly be maintained in the deciduous dentition, but growth disturbances, presumably due to mucoperiosteal denudation on palatal bone,[12] could not be influenced. On the whole, however, conditions for successful later orthodontic treatment proved to be much better if early collapse could be avoided, whereas expansion of collapsed arches in the deciduous dentition proved to be useless with a view to later orthodontic results. In order to take the greatest advantage of early orthopedic treatment, the systematically coordinated approach described in this article was introduced and became routine. Surgery was performed by Prof. M. Perko from the Department of Maxillofacial Surgery in our Dental Institute.

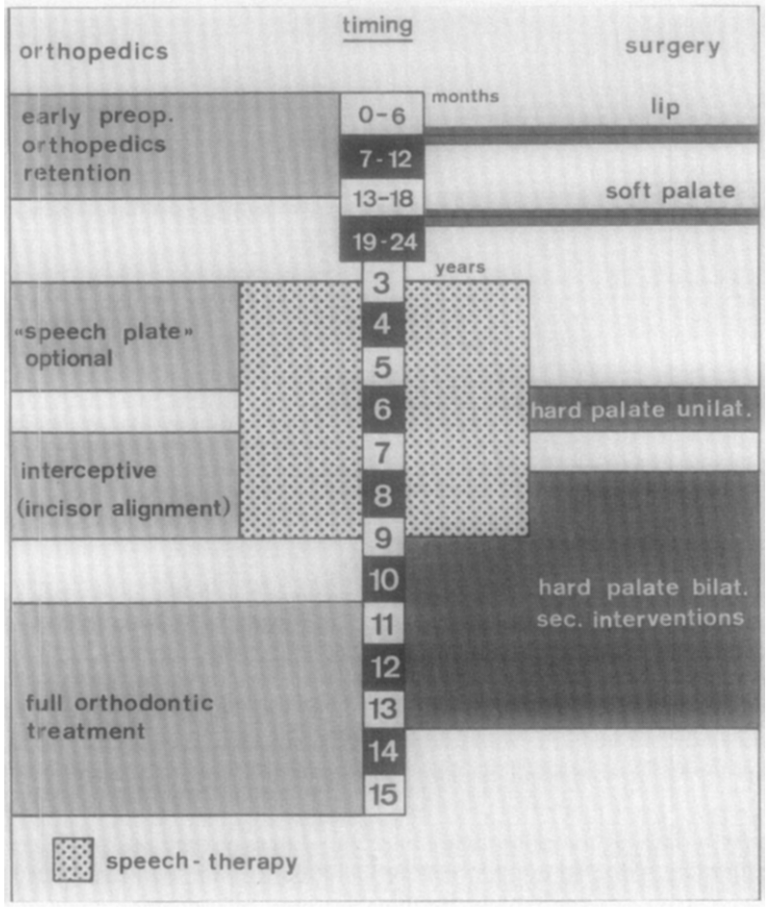

Fig. 1. Timing of procedures. Active treatment is limited to definite periods as necessity demands, in order not to overstress patients. Surgery is delayed until functional requirements impose anatomic continuity. Speech therapy entails, from 3 to 5 years of age, coaching of parents and child; from 5 years of age and later, actual treatment according to the individual situation, either on an outpatient basis or in boarding school emphasizing speech therapy.

Material and procedure

This survey includes a group of patients with cleft lip and palate from birth to 6½ years of age (eighteen unilateral total cases and nine bilateral total cases). The same approach was used for all of the patients, surgery performed by the same surgeon. Coordination of procedures is essential; timing is dictated by functional necessity—particularly speech development (see Fig. 1).

Preoperative maxillary orthopedic treatment has the following objectives (listed in chronologic sequence): monitoring function (feeding, tongue posture) (Figs. 2 and 3); guidance of growth and position of maxillary segments, especially with a view to intermaxillary relationship (Fig. 9, *B, D, F*); delay of surgery in order to allow intrinsic growth potentialities to become manifest.

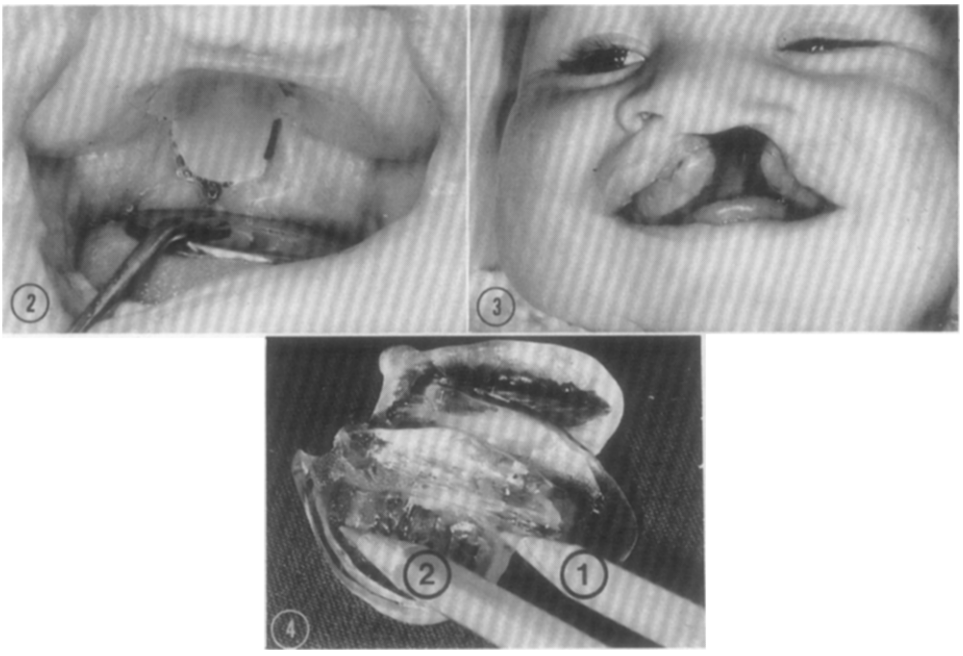

Fig. 2. Regular plate of compound soft/hard acrylic resin. Note the posterior appendix obturating the velar cleft. It is adapted on elevation and approximation of velar halves in function.

Fig. 3. Plate in situ: It normalizes tongue posture, facilitates feeding, and allows growth guidance.

Fig. 4. Upper surface of the plate (bilateral case). Extension into the nasal cavity gives better stabilization. Indicated are the sites for initial adaptation, particularly at the transition from hard to soft palate (**1**) and the area for later adjustments (grinding) to permit further growth (**2**).

Surgical intervention, as atraumatic as possible, is performed as late as possible with a view to undisturbed growth. The timing is set by speech development. Concomitant orthopedic treatment is carried on until the age of 18 months in order to control possible effects of surgery and to maintain preoperative results until intercuspation of the first deciduous molars is established.

Actual management

At birth a cleft is not an immediate surgical problem but a pediatric concern: the child must thrive. In order to normalize feeding, *a plate of compound soft and hard acrylic resin* is made as soon as possible, usually within 24 to 48 hours after birth. The impression is taken with alginate, without anesthesia. On the plaster cast, the plate is modeled in wax, the vomer relieved by double tinfoil (0.6 mm). A first layer covering the whole oral and vestibular surface, extending into the nasal cavity, preforms parts of the plate which later will consist of soft acrylic resin. Across the palatal vault, between the alveolar ridges, a second layer of wax is added as a matrix for the hard portion of the plate. A special procedure

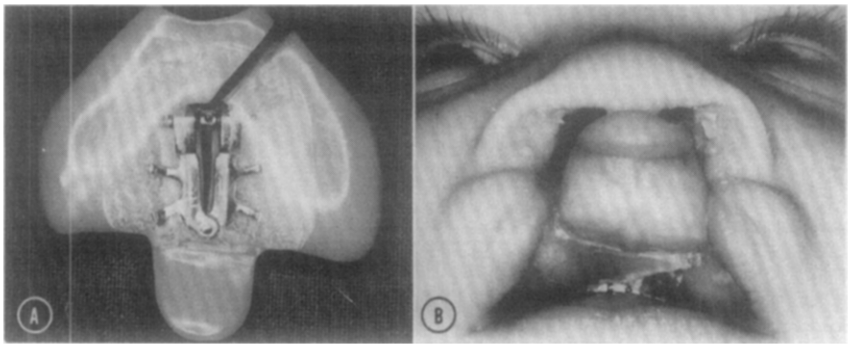

Fig. 5. Plate with a fan-screw used in bilateral cases. Oblique cut designed to separate the premaxilla from the left segment. Soft acrylic resin permits anterior expansion without cutting the posterior appendix. The hard acrylic layer is clearly visible.

developed in our laboratory permits hot curing of both acrylic resins (Vertex—soft and SR-Ivoclar) in one process, thus providing a firm union of the two parts. Another important feature of the plate is its posterior appendix, designed to obturate also the soft palate cleft (Fig. 2).

The plate must be carefully adjusted on the patient. This particularly applies to its posterior parts, where soft tissue may have been displaced by impression material, e.g., at the transition from soft to hard palate (Fig. 4). Nasal airways must be freed by reducing the nasal extension. These initial adaptations are a crucial part of preoperative treatment. They require experience and consideration of functional requirements.

The plate is held by suction and adhesion only (Figs. 2 and 3). Trial feeding is done by ourselves with a regular short nipple. Instructions for handling the plate are given: The device is worn 24 hours a day, removed after every meal, and cleaned with a toothbrush and lukewarm water. Checking for possible pressure spots is done within the first 48 hours. On principle, treatment is done on an outpatient basis from the beginning. The mother takes over as soon as possible. Mother and child should not be separated and mother's milk should be supplied whenever available. Once properly adjusted, the plate functions as an artificial palate.

The hard acrylic layer (Fig. 5, *A*) provides stabilization of segments in both the transverse and the anteroposterior dimensions. The soft parts adapt themselves to the underlying structures, gradually giving way to the increase of the transverse maxillary dimension. Newborn infants usually accept the plate within a few days. (Older infants may require more time. Experience shows that, as a rule, it is not advisable to start preoperative treatment after the age of 2 months.)

With a view to the psychological situation, the plate and the feeding instructions help to overcome the initial shock of the parents. Something *is* being done. The baby can be fed without any special device and is thriving. Detailed explanations and coaching eliminate the urge for untimely closure, and we may then choose the optimal time for surgery.

Fig. 6. Guidance of maxillary segments. Parts of the plate corresponding to dark stippled areas are gradually ground away; light stippled areas indicate relief of the cleft borders by grinding.

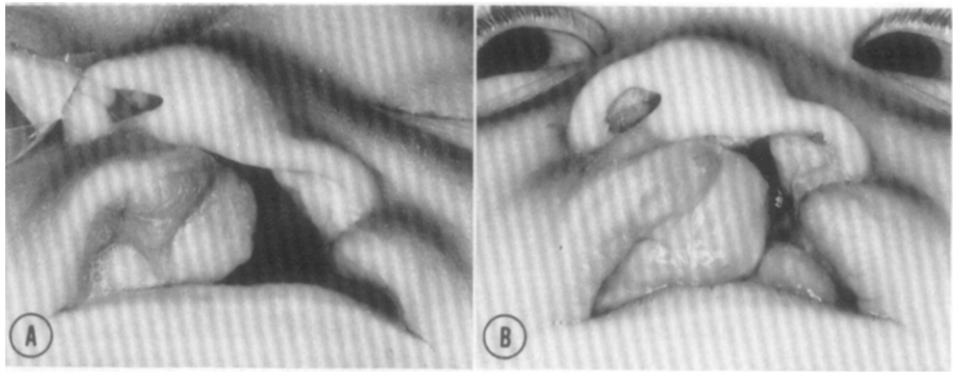

Fig. 7. Unilateral total cleft lip and palate. As a consequence of growth and orthopedic guidance, the alar base is carried forward and supported by the lesser segment, thus facilitating surgery. **A,** At birth; **B,** 6 months later.

Handling of the plate decisively influences the effects of early orthopedics. As soon as the child has accepted the appliance, usually within a fortnight, arch alignment is induced by grinding away material in definite areas (Fig. 6): *in unilateral cases* on the butt ends of both segments (palatomedially for the major one, anterolaterally for the lesser one, vertically for both). Mesial shifting of the major segment and straightening of the vomer ensue (Figs. 8 and 11). The margins of the palatal shelves are relieved medially and vertically.

In bilateral cases the butt ends of both lateral segments are relieved by grinding in an anterolateral direction. The margins of the palatal shelves are relieved medially and vertically. The premaxilla is supported posteriorly, lateral space being provided according to increase in size. In cases of lateral deviation grinding has to be modified accordingly, particularly along the vomer (Fig. 6). No active retrusion of the premaxilla is carried out.

Expansion (Fig. 5) is often necessary in bilateral cases lacking space, either for alignment of a large premaxilla and/or for proper accomodation of the fast-developing mandible, which primarily is always situated very posteriorly between

Fig. 8. Mesial shifting of the major segment. The frenum, formerly located in the incision of the plate at arrow, has spontaneously moved out of it as an effect of growth-guidance (same patient as in Fig. 9).

the lateral segments. Expansion is also required in the rare unilateral narrow cases with a tendency to overlapping of segments (Fig. 12). Aiming at a maximum spontaneous development of maxillary segments, grindings are repeated every 4 to 6 weeks. The appliance has to be replaced after 4 to 5 months because of deterioration of the material (porosity and stiffening of Vertex—soft). Furthermore, by forward growth of the maxillary complex, the plate is carried forward, causing its posterior appendix to become insufficient for adequate obturation. With a view to lip surgery it is also important to have a well-fitting device for postoperative retention.

For *surgical closure of the lip in unilateral clefts* we consider 5 to 6 months as being the optimal time. The reasons have been well defined by Crickelair.[4] The alveolar cleft has considerably narrowed by this time as a consequence of guided and undisturbed maxillary growth. The alar base is carried forward and supported by the lesser segment (Fig. 7). In addition, since in normal speech development labial sounds appear at about this time, lip seal becomes essential. Current Z-plasties are used for closure, mainly Millard and Tennison techniques with individual modifications according to configuration. The plate is reinserted immediately after the intervention. It lessens the pressure of the united orbicularis oris muscle on the butt ends of maxillary segments and allows further guidance.

For *lip closure in bilateral clefts* the čelešnik approach[3, 9] in two stages has proved to be the most adequate (Figs. 14, 16, and 17), even in cases with marked tissue deficiency (Fig. 15). Stage I: Symmetrical closure of the nostrils and the nasal floor produces approximation of the three segments which are supported and guided by the orthopedic plate; arch alignment ensues. Stage II: Closure of the lip proper is preferably done by Veau or Manchester cut, taking care to shape a deep sulcus. Palatal tilting of the premaxilla is prevented by the supporting plate, fitted if necessary with a fan screw in order to allow further adjustment of the segments as well as to exert some counterpressure against scar contracture.

Postoperative orthopedic care is carried on as already described. Caries pre-

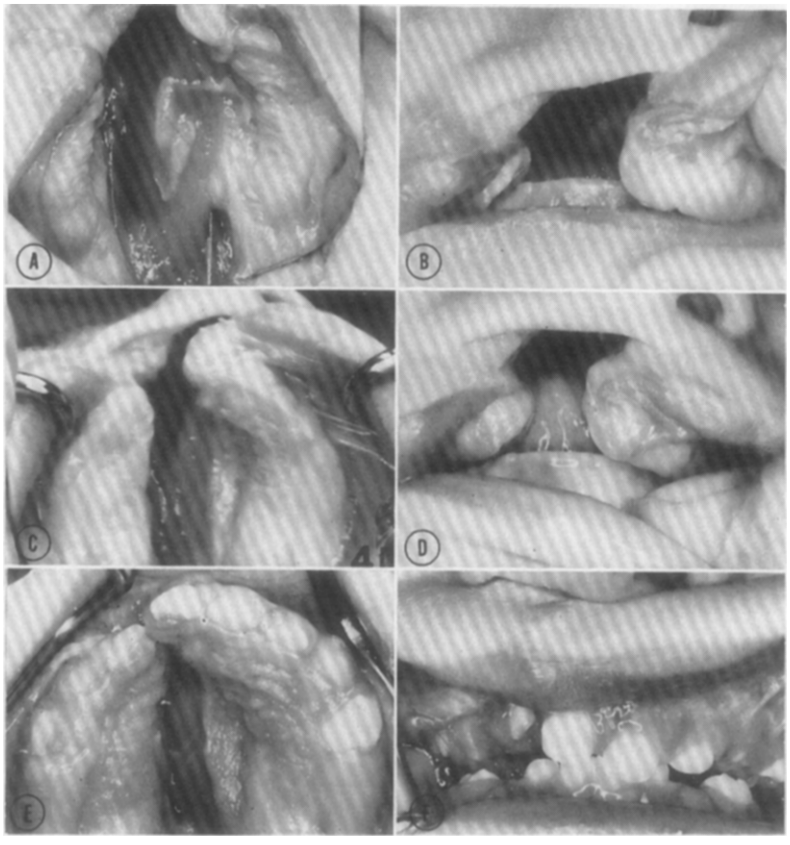

Fig. 9. Patient M. V.; unilateral total cleft lip and palate. Development in 3½ years, palatal and occlusal aspects, **A, B,** At 1 day of age, initial alveolar cleft width 13 mm.; **C, D,** at 4 months of age, narrowing of the cleft (7 mm.); increase of vertical dimension, regular intermaxillary relationship; **E, F,** at 18 months of age, prior to velar closure, butt joint of alveolar segments; **G, H,** at 3 years and 7 months of age, 1½ years after veloplasty; note spontaneous narrowing of the remaining cleft in the hard palate by further development of the shelves; **I, J,** prior to and 6 weeks after lip closure; the plate was adapted and reinserted immediately after surgical intervention.

vention, initiated in the newborn period by dietetic counseling and fluoride medication, should be intensified as soon as teeth are present; tooth brushing is started without toothpaste. Space is provided for erupting teeth by grinding the plate (Fig. 10). For the aforementioned reasons a new plate has to be made again at 10 to 12 months of age. Serving now mainly as an obturator, it is worn until a few weeks before soft palate closure.

Palatal closure in two stages is used for all complete clefts, again with a view to preventing growth disturbances in the bony maxillary structures. *Velar closure* is performed at about 18 months of age for the sake of speech development (Figs. 9, 11, 12, and 13); *hard palate closure* is delayed until the sixth to eighth year (Figs 1 and 13). The technique used for veloplasty is based on descriptions by

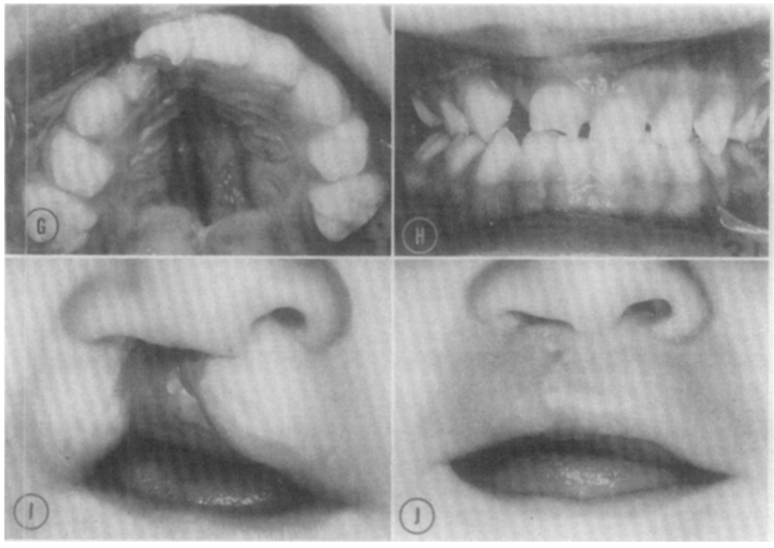

Fig. 9, G-J. For legend, see opposite page.

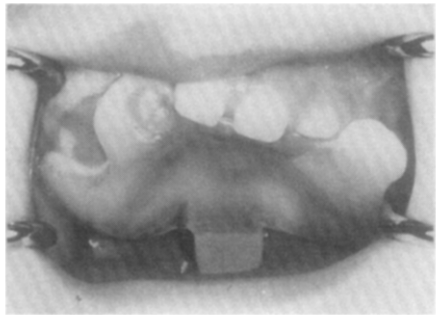

Fig. 10. Soft/hard acrylic plate for retention and obturation of the palatal cleft, adapted according to tooth eruption and worn until closure of the soft palate (18 months).

Widmaier,[28] Ruding,[23] and Braithwaite and Maurice.[2] Its main features are: (1) raising of *mucous* flaps on the posterior third of the palatal shelves only, leaving the periosteum and neurovascular bundle untouched and preserving retromaxillary tissue (hamulus, etc.); (2) detachment of the erroneous insertion of the interlaced levator and palatopharyngeal muscle fibers from the posterior nasal spine; (3) retropositioning of the reconstructed muscle sling to its correct anatomic position.[9, 13, 18]

After soft palate closure no retention appliance is worn. If demanded by the speech pathologist for better speech proficiency (plosives), an inactive plate may be used to cover the remaining anterior gap. It is worn in the daytime only and facilitates further narrowing of the cleft by keeping the tongue out. Only about 50 per cent of the patients actually need it, usually not before 4 years of age (Fig. 13, *C*).

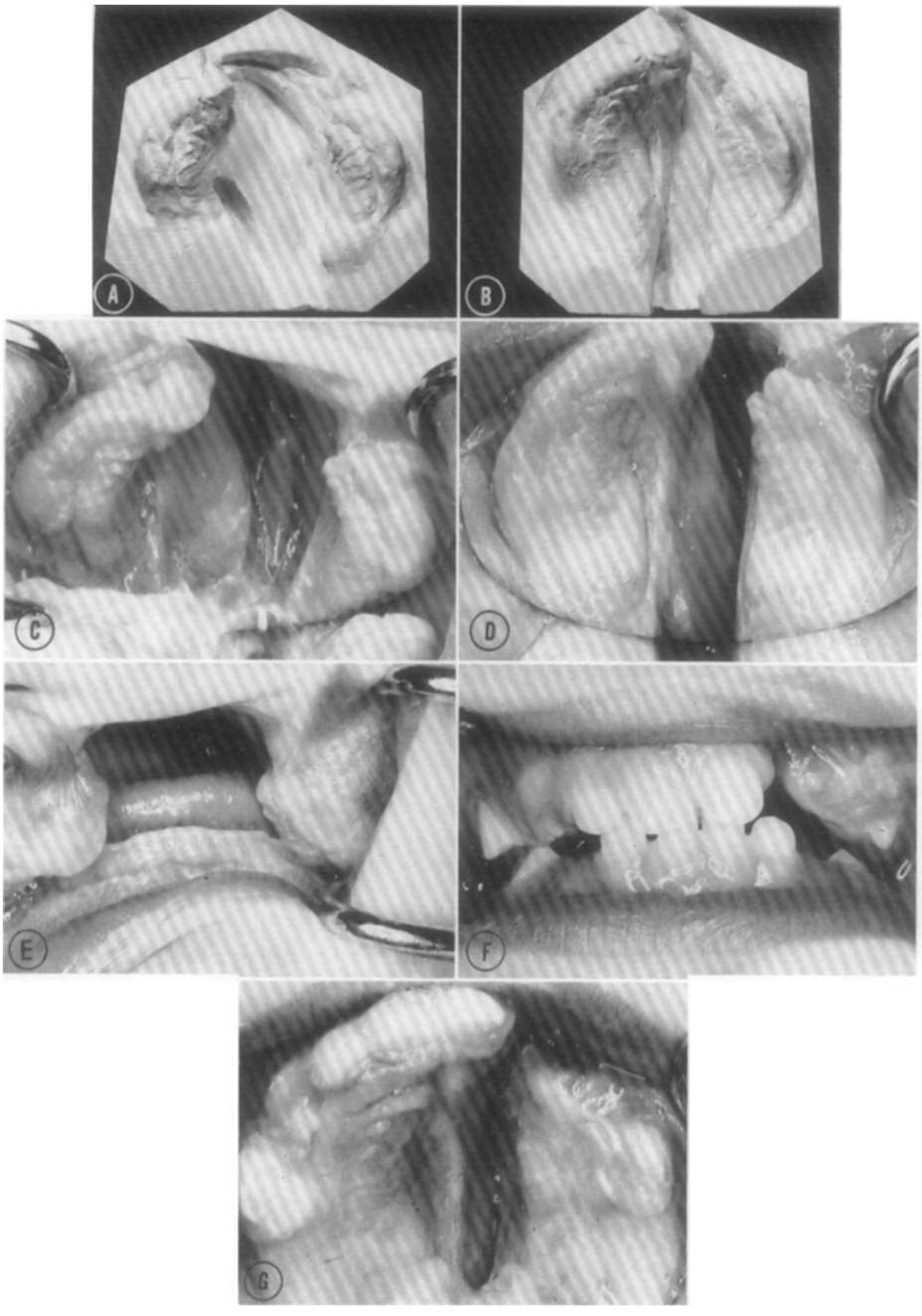

Fig. 11. Patient M. P.; unilateral total cleft. Routine treatment. **A,** Models at birth and 6 months later (same scale); note shifting of the major segment and straightening of the deviated vomer; **B,** corresponding oral photographs; **C,** occlusion at birth and at 21 months of age; **D,** palate 3 months after velar closure (21 months of age).

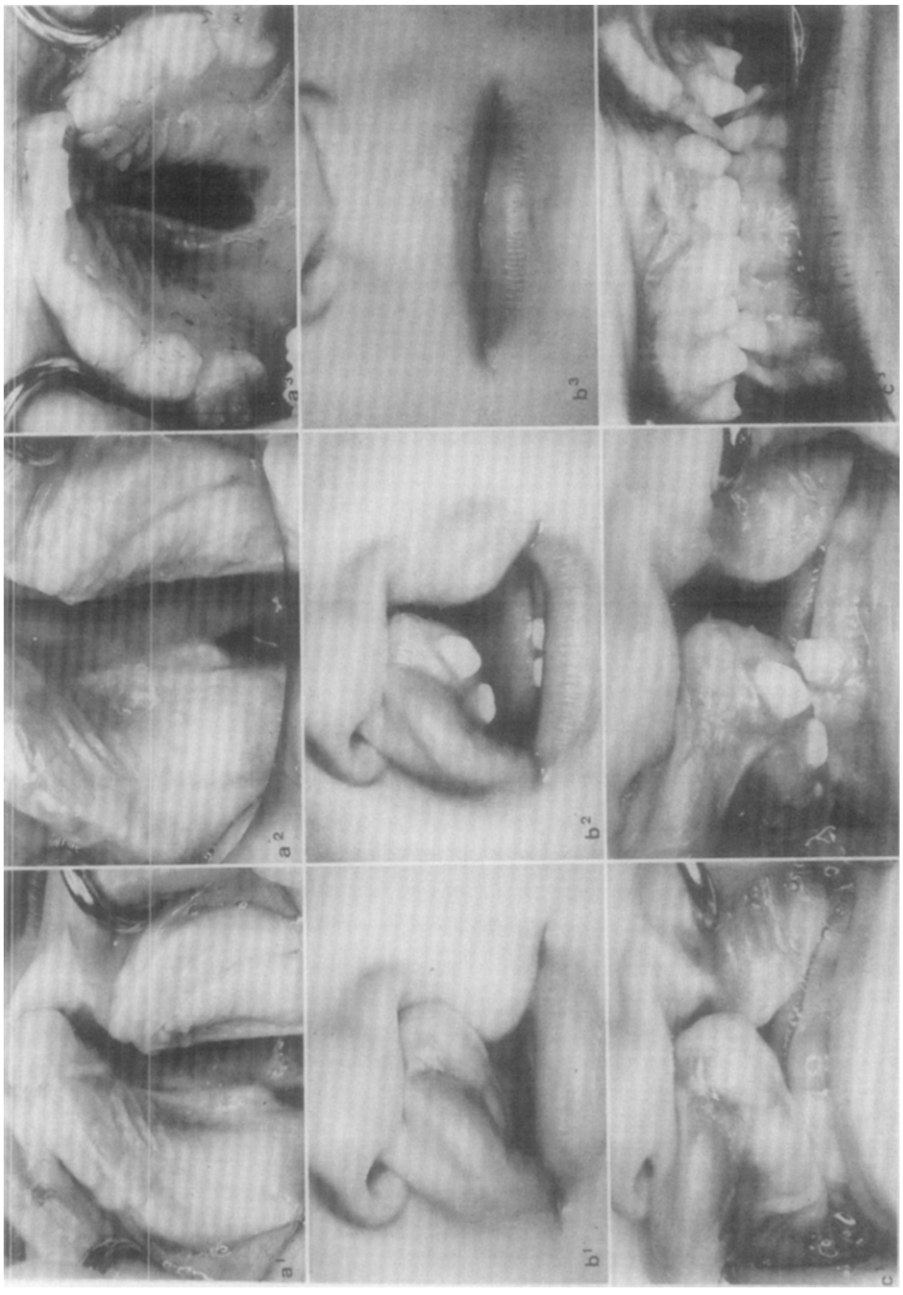

Fig. 12. Patient Sch. H.; overlapping segments, unilateral total cleft. **A,** Palatal view; **B,** lip configuration; **C,** occlusion. **1,** At 4 months of age. First visit to our unit. No treatment up to this time. Unfavorable development which could have been prevented by early orthopedics. **2,** At 7½ months of age, after 3½ months' expansion. **3,** At 3 years of age. No retention after velar closure at 18 months of age. Operation performed by Prof. Schüle, Stuttgart, West Germany.

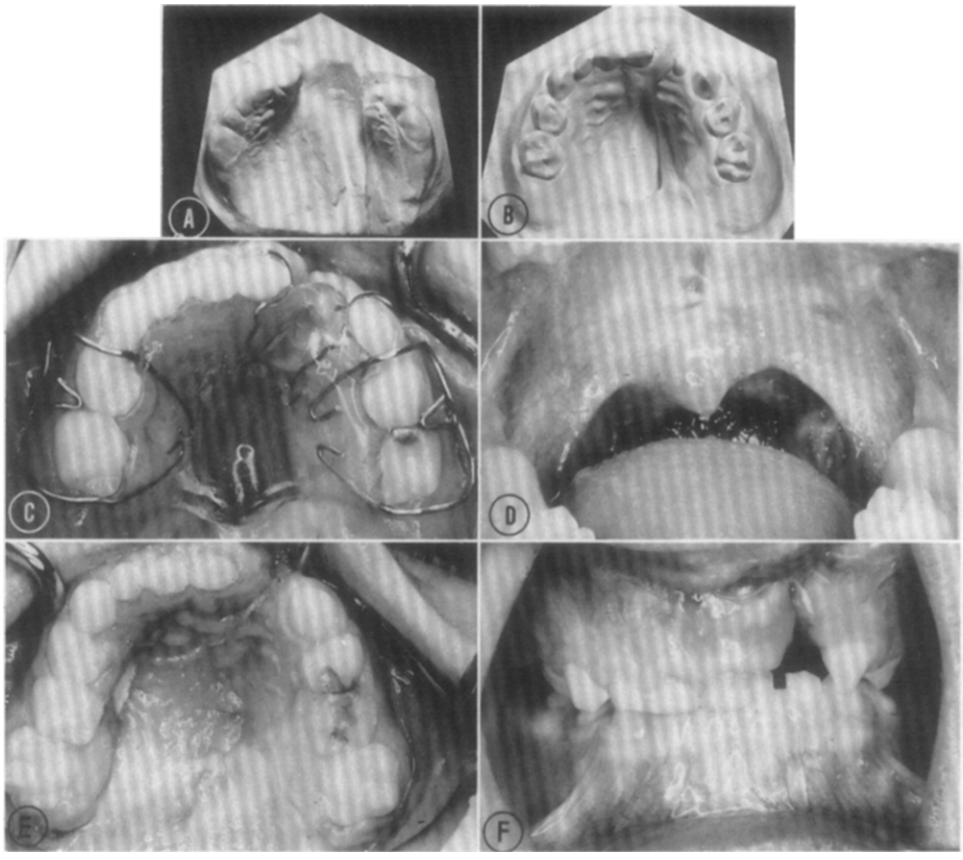

Fig. 13. Patient St. M.; development of unilateral total cleft from birth to 5 years of age. Routine treatment. Class II tendency. **A, B,** Models at birth and at 5 years of age (photographs taken at same scale); **C,** temporary obturation by inactive "speech-plate," started at 4 years of age; **D,** soft palate at 5 years of age; **E, F,** hard palate and occlusion after surgical closure at 5 years of age.

At about the sixth to eighth year of age (Fig. 1), when growth has further progressed, *closure of the hard palate* can be achieved by shifting narrow mucoperiosteal flaps which may be unilateral only. Paragingival tissue is spared (Fig. 13, *E*).

From the orthodontic point of view, postponement of hard palate closure allows correct intercuspation of the first permanent molars to become established before the intervention. In our opinion this is an additional advantage in consideration of intermaxillary relationship.

Preliminary results

Although we have used the same preoperative orthopedic treatment for more than a decade, time and again modifications in surgery impeded our gathering "pure" samples of a reasonable size for numerical evaluation.

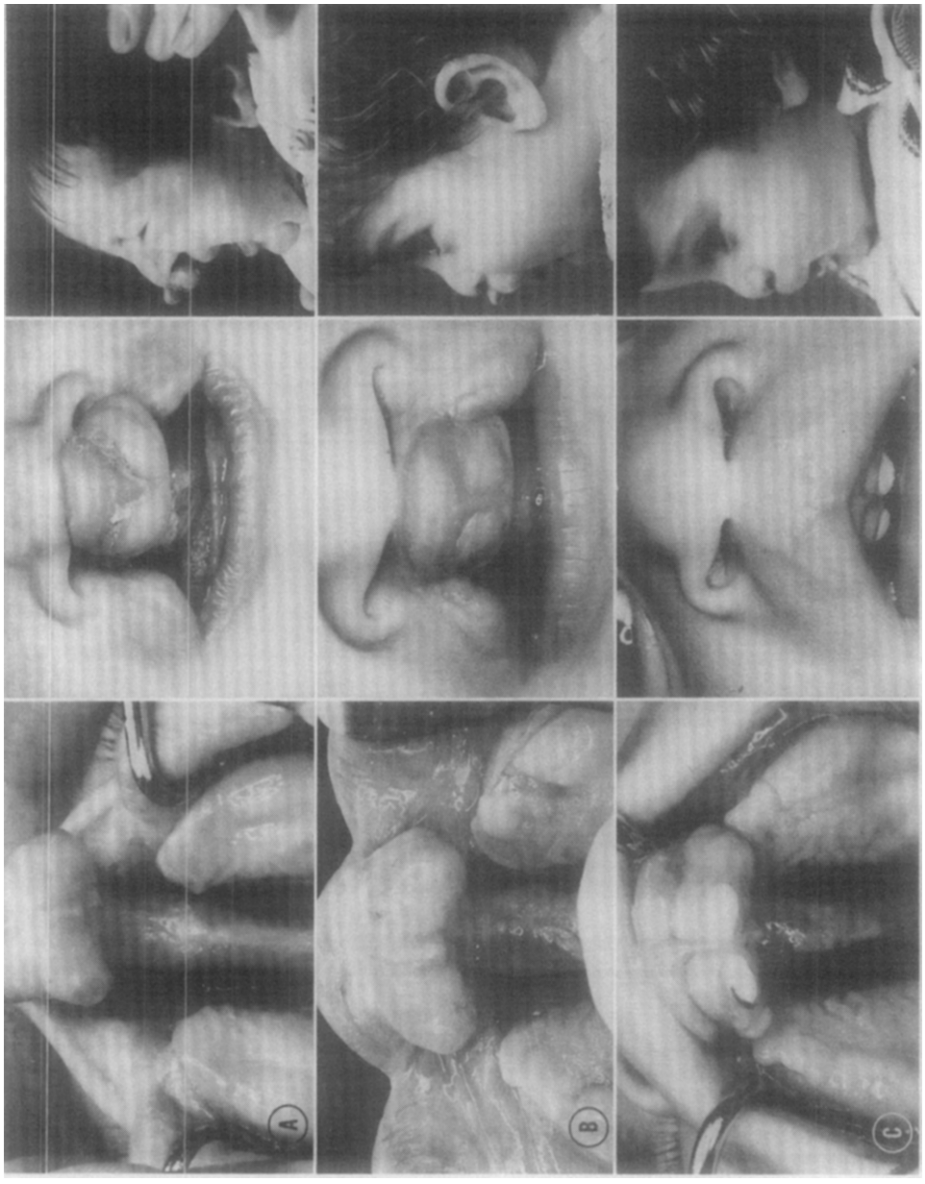

Fig. 14. Patient G. C.; bilateral total cleft lacking space for alignment of the premaxilla. Lip closure according to Celešnik in two steps. **A,** At 7 days of age, slight preoperative expansion of lateral segments and mesialization of the premaxilla are required. **B,** At 7 months of age, 6 weeks after Step I of Čelešnik[3] procedure. Effect of guided growth and symmetrical closure of the nasal floor at 5½ months of age. Approximation of the three segments. No active retrusion of the premaxillla. **C,** At 1 year and 3 months of age, after full closure of the lip (Step II).

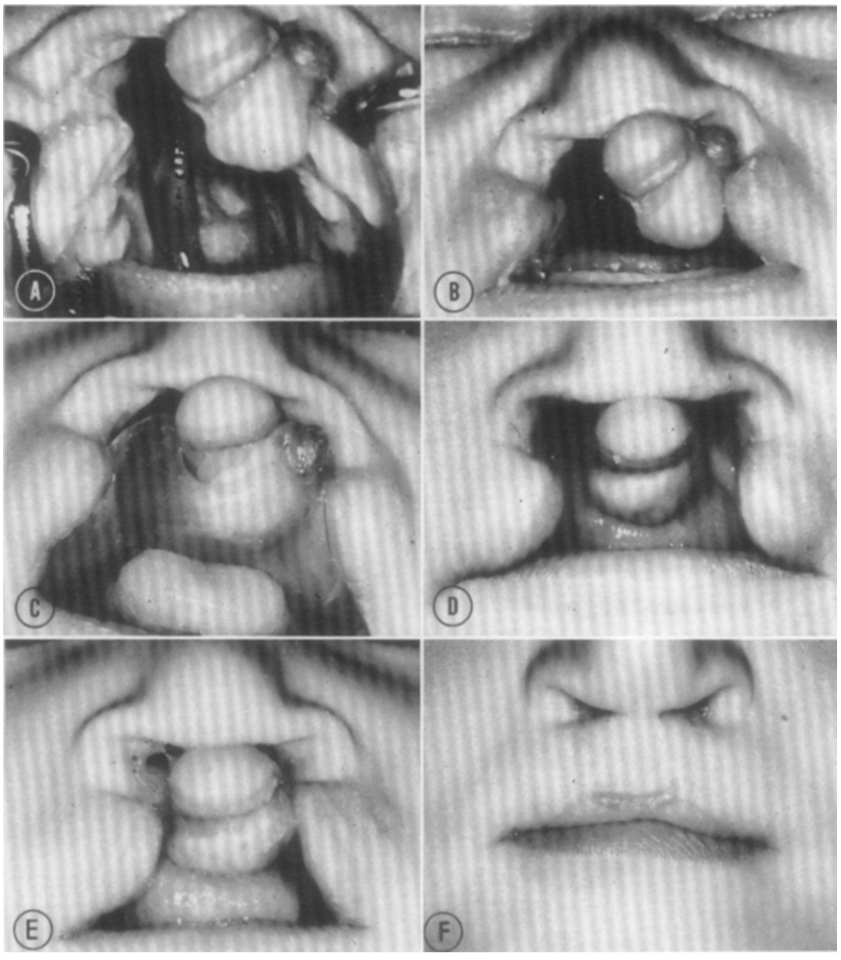

Fig. 15. Patient C. A.; bilateral total cleft with tissue deficiency of premaxilla and prolabium. **A, B,** The situation at birth. **C,** Gradual mesialization of deviated premaxilla and vomer by means of a plate, self-curing acrylic resin gradually being added on one side and removed on the other. **D, E,** Stable symmetric situation before and after Stage I of Čelešnik's[3] operation. Retention by plate continuing until velar closure. **F,** One year after full lip closure.

Today a group of eighteen cases of total unilateral (UCLP) and nine of total bilateral (BCLP) clefts in patients 4½ to 6½ years of age are available for analysis. They were treated strictly according to the aforementioned principles, surgery having been performed by the same surgeon (Prof. M. Perko, M.D., D.M.D., Department of Maxillo-Facial Surgery, Zürich University Dental Institute). With a view to orthodontic as well as to speech parameters, present patients are compared with a previous sample from the same age group which differed in type and timing of surgical interventions, although the same preoperative orthopedic treatment was applied to all cases. This being a preliminary survey, based on a limited number of cases, we dispensed with a sophisticated statis-

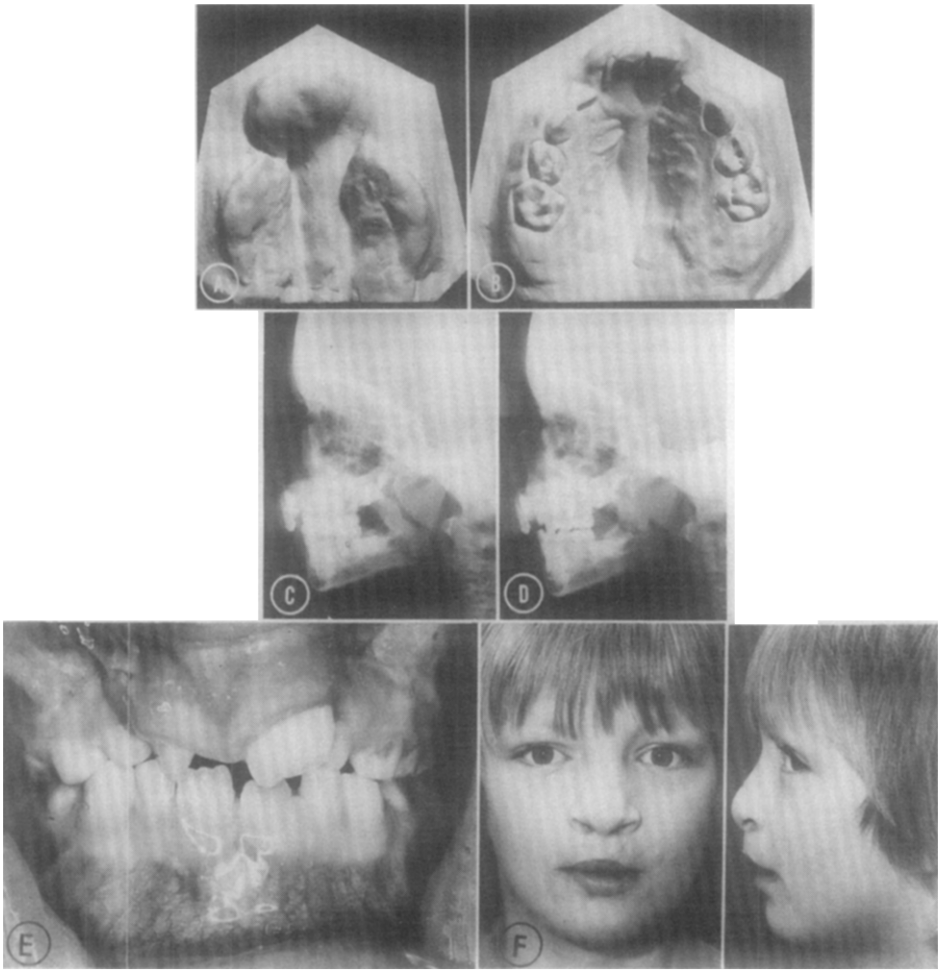

Fig. 16. Patient W. O.; bilateral total cleft of lip and palate, average severity. **A,** Initial model. **B,** At 5½ years of age, after routine orthopedic and surgical treatment (Čelešnik[3] Steps I and II and veloplasty), previous to closure of the hard palate. Good spontaneous growth of palatal shelves. (**A** and **B** taken at same scale.) A speech-plate was not required. **C,** Head films with teeth in occlusion and during phonation of "e" at 5 years of age. Regular mandibular growth and correct occlusion. Note soft palate of normal length, elevation impeded by excessive adenoids causing rhinolalia clausa. After partial adenotomy (anterior portion) considerable speech improvement ensued. **D, E, F,** Occlusion, full-face, and profile photographs at 7 years of age.

tical evaluation. For the moment, the main objective is to check the positive clinical impression in individual patients by numerical evaluation of certain parameters in the whole group of similarly treated cases (see Figs. 14 to 17).

Cephalometric findings

The findings in the present cases, compared to those of a former study,[25] show differences which can mainly be attributed to revised surgical timing and tech-

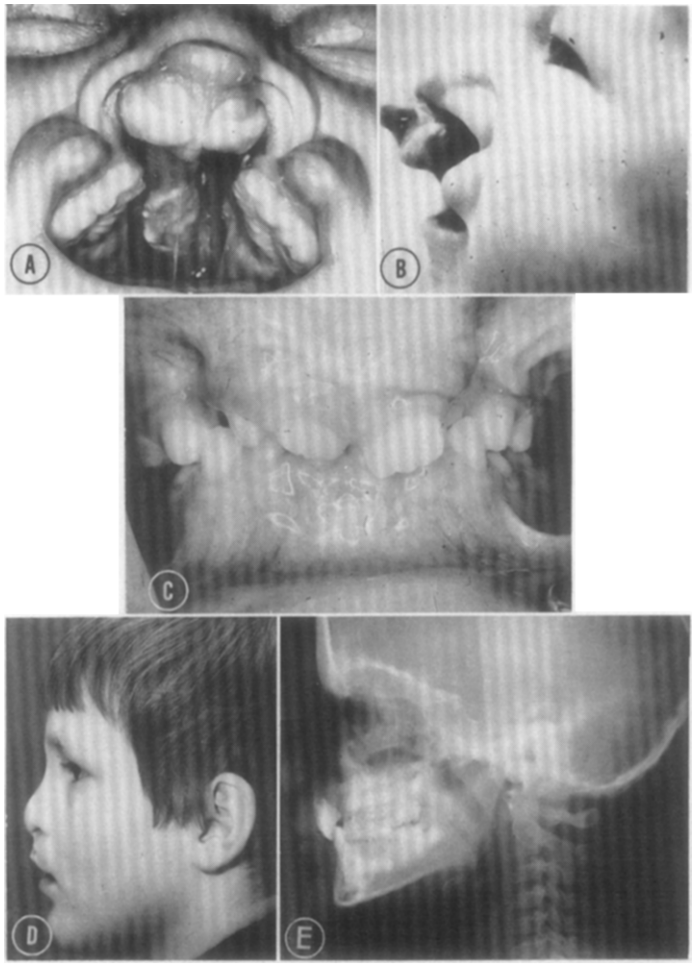

Fig. 17. Patient E. P.; bilateral total cleft lacking space for alignment of premaxilla. Routine treatment: expansion of lateral segments combined with Čelešnik[3] procedure. **A, B,** At 7 days of age. **C, D,** occlusion and profile at 7 years of age. Columella lengthening will be performed after complete root formation of central incisors. **E,** Head film taken at 7 years of age shows good maxillary and mandibular development. Soft palate closure performed at 18 months of age resulted in normal velar length and function. Hard palate closure was performed at 7 years of age.

nique (Table I). A control group was used as a common base of reference. It consisted of thirty-seven randomly selected cases with complete deciduous dentition and Class I molar relationship, ANB angles ranging from 0 to 7 degrees.[25] This was considered a sample of the "normal" population. Identification of reference points was based on definitions given for the former sample. Points A and PNS are particularly difficult to locate in young patients with clefts. Point A is precarious in the 5-year-old group because of tooth germs molding the anterior contour of the maxilla; point PNS may be dubious because of reduced radiopacity

Fig. 18. Cephalometric landmarks used (bilateral case). Most reference points are located according to classical definitions. With consideration of problems related to the typical morphology in young patients with cleft lip and palate, point **A** is located at the deepest point on the anterior contour of the upper alveolar process **above the tooth germs of the permanent incisors.** In a preliminary longitudinal survey with a view to angle SNA, this point seemed acceptably correspondent to Downs' point **A** after eruption of the permanent incisors. Torsion of tooth germs may complicate the situation. **A'** is the projection of point **A** on the **ANS-PNS** line. PNS is located at the posterior end of the hard palate if visible, otherwise at the point of intersection of dorsal maxillary contour and soft palate contour.

of separated and laterally displaced "posterior nasal spines"—even more so in cases of bilateral cleft. Amazingly, these basic problems of evaluation are but rarely mentioned in the literature. Not being able for the moment to propose more suitable reference points, we try to offer a definition for point A in this particular study (Fig. 18) and we are cautious in interpretation of measurements involving point PNS.

Table II includes only parameters which show distinctive differences either between control groups and former cleft groups or between cleft groups.

General findings. Within cleft lip and palate groups, individual measurements vary greatly. Many angular measurements, however, lie within a range of one standard deviation from mean control values.

Mean linear measurements for present BCLP, except ANS-PNS distance, also lie within one standard deviation from mean control values. In unilateral clefts, former as well as current, mean distances are distinctly smaller than in control subjects, except the anterior cranial base and total anterior face height.

Mean angular measurements as well as mean length ratios of the present cleft sample mostly show the same tendencies as they did in the former cleft sample, but to a lesser extent with regard to control values (Table II).

Changes from earlier to present cleft groups. In contrast to "normal subjects," the whole maxillomandibular complex in both uni- and bilateral cleft patients still appears to be positioned more upward and dorsally relative to the cranial base, but less so in the present samples than in the former ones. In the present

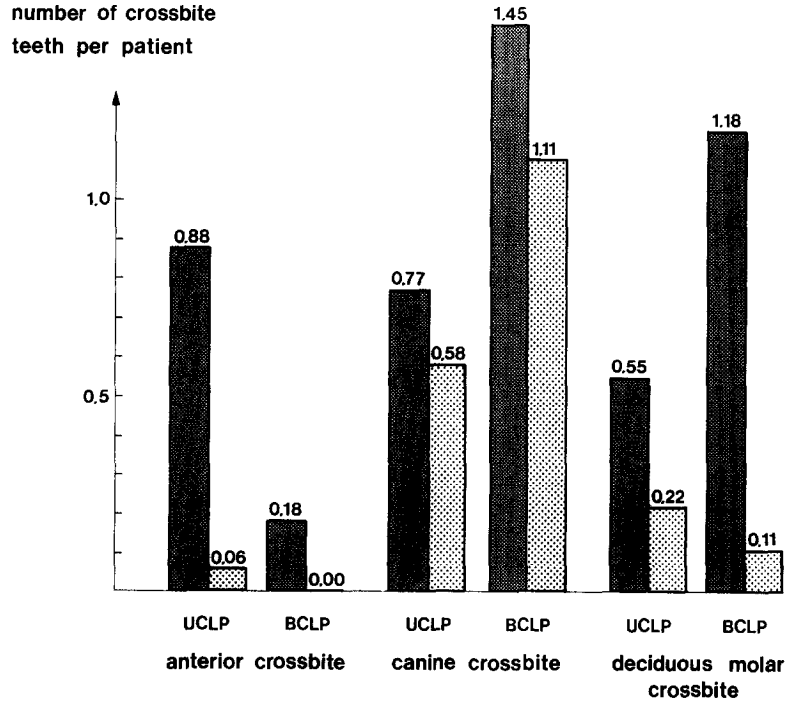

Fig. 19. Number of crossbite teeth per patient. Present samples (light stippled) plotted against former samples (dark stippled). Anterior crossbite in unilateral cases and deciduous molar crossbite in bilateral cases were most obviously reduced by the new treatment concept. The relatively high ratio of canine crossbite in the present cases is a consequence of a special variation in surgical procedure (Burian flaps, now abandoned) in some of the cases (6 UCLP; 5 BCLP).

Table I. Samples used for cephalometric evaluation in cases of unilateral total (UCLP) and bilateral total (BCLP) cleft lip and palate

		Age (yr.)			*Early ortho-pedics*	*Lip closure*		*Palate closure*	
*Subjects**	*No.*	*Min.*	*Mean*	*Max.*		*Age (mo.)*	*Type*	*Age (mo.)*	*Type*
Control	28♂ 9♀ 37	3.6	5.2	6.3	–	—	—	—	—
Former:									
UCLP	14♂ 4♀ 18	3.6	5	6.2	+	Approx. 3	Straight cut	Ca. 30	Whole palate
BCLP	9♂ 2♀ 11	3.7	5.2	6	+	3/5	Veau right/left		Mucoperiosteal flaps
Present:									
UCLP	13♂ 5♀ 18	4.3	5	5.6	+	6	Z-plasty	18	Soft palate only, mucosal flaps
BCLP	8♂ 1♀ 9	4.8	5.3	6.5	+	6/8	Celešnik nostrils/lip		(Hard palate after age 5 years)

*Control and former UCLP/BCLP subjects are taken from an earlier study.[25]

Table II. Means and standard deviations for selected length ratios and angular measurements in control subjects and patients with total cleft lip and palate (Table I)*

	Control subjects		Unilateral total clefts				Bilateral total clefts			
			Present		Former		Present		Former	
	Mean	S.D.	Mean	S.D.	Mean	S.D.	Mean	S.D.	Mean	S.D.
Length ratios:										
$\frac{S-Go}{N-M}$	0.6389	0.05	0.6021	0.03	0.6084†	0.03	0.5952†	0.04	0.5840§	0.02
$\frac{N-A'}{N-M}$	0.4358	0.01	0.4202§	0.03	0.4119§	0.02	0.4208§	0.02	0.4373	0.03
$\frac{S-PNS}{S-N}$	0.6088	0.02	0.5554§	0.03	0.5501§	0.02	0.5535§	0.04	0.5344§	0.03
$\frac{ANS-PNS}{S-N}$	0.7365	0.02	0.7064§	0.03	0.7245	0.04	0.7748§	0.05	0.8027§	0.05
$\frac{ANS-PNS}{Gn-Go}$	0.7813	0.03	0.7955	0.07	0.8105†	0.06	0.8449§	0.04	0.9013§	0.06
$\frac{Gn-Go}{S-N}$	0.9447	0.05	0.8899§	0.06	0.8941‡	0.06	0.9188	0.07	0.8920§	0.05
Angles:										
N S Ba	129.0	3.34	129.9	3.39	131.3†	4.10	130.5	5.31	131.1	5.64
N S Ar	123.1	4.52	125.0	3.14	125.3	4.53	125.3	5.43	124.6	4.86
S Ar Go	138.5	5.62	138.8	5.60	137.3	6.10	138.9	6.03	138.2	5.57
Ar Go M	133.0	4.15	134.7	5.03	135.4†	3.60	133.4	3.82	138.1§	5.10
S N B	77.1	2.91	73.4§	3.48	73.0§	2.95	73.1§	3.73	72.4§	1.14
S N A	81.7	2.90	79.8‡	2.27	76.6§	3.96	85.1†	6.60	80.2	5.0
A N B	4.6	1.55	6.3§	2.87	3.6†	3.08	12.0§	4.03	7.8§	2.68
N S Pg	63.0	2.92	66.2§	3.74	65.9§	3.46	66.4§	4.37	66.9§	3.60
N-S/M-Go	35.2	3.68	38.1†	5.35	38.6§	4.37	38.5†	5.64	41.5§	4.36
N-S/ANS-PNS	7.9	2.16	9.4†	2.35	8.1	3.21	8.6	3.71	13.1§	2.95

*Significance of the differences between clefts and controls is indicated within the columns. Significant differences between former and present cleft samples are indicated between columns "former" and "present" for UCLP and BCLP, respectively.

† $0.05 > P > 0.01$.

‡ $0.01 > P > 0.005$.

§ $0.005 > P > 0.001$.

bilateral cleft patients, the premaxilla is obviously less tilted downward in consequence of the Čelešnik approach to lip closure versus the former procedure (Veau right/left). This same fact further shows in the N-A′/N-M ratio as well as in the angles A-N-B and S-N/ANS-PNS. The mean relative length of the horizontal portion of the mandible is reduced in all cleft samples, more so in respect to S-N than to ANS-PNS; reduction is less obvious in the present cases. Mandibular shape and posture contribute to a relatively downward and backward position of pogonion in all clefts.

Occlusal findings

Complete deciduous dentitions were present in all patients except for congenitally missing upper lateral incisors. Class I intermaxillary relationships pre-

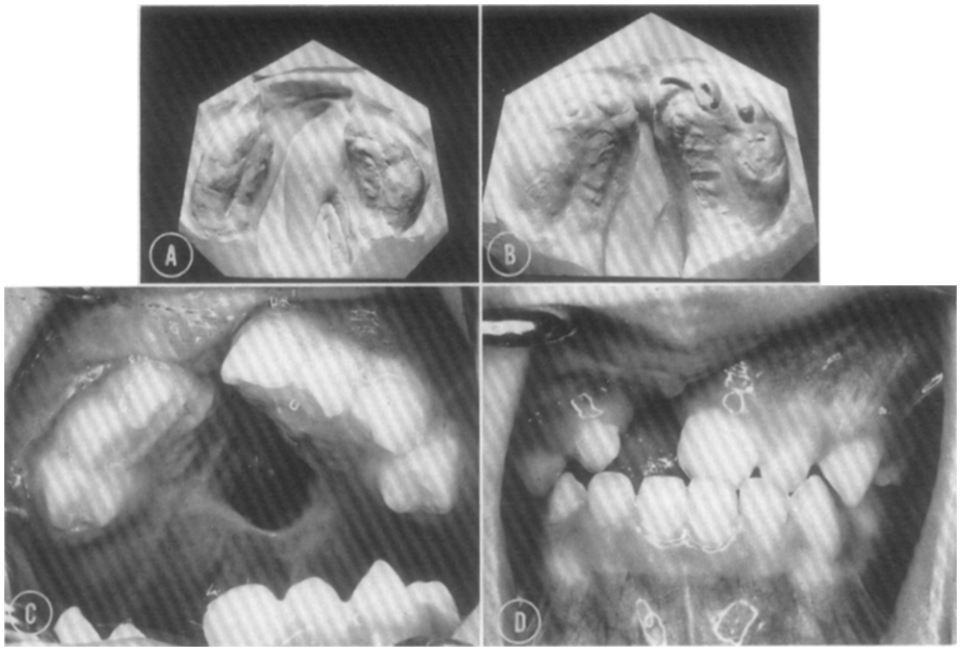

Fig. 20. Patient St. R.; marked initial tissue deficiency in right unilateral total cleft. Example of the great growth potential present in most cleft cases. **A,** Model made at birth. **B,** Model made a 18 monhs of age. (Photographs **A** and **B** taken at the same scale.) **C, D,** Palate and occlusion at 2½ years of age. Teeth present show that only the right half of the premaxilla is missing.

vailed in all samples. Class II relations were found in unilateral (five former and two present cases) as well as in bilateral clefts (two former cases). Class III relationship was found in unilateral clefts only (one former and one present case). Cross-bites were recorded separately for deciduous anterior, canine, and molar teeth.

For a preliminary survey, a simple score (number of cross-bite teeth per patient) seemed sufficient (Fig. 19). Definite differences between former and present cases can be found for anterior cross-bite in unilateral clefts and for deciduous molar cross-bite in bilateral clefts. These differences are particularly noteworthy since in the present patients no orthodontic treatment was applied after soft palate closure at 18 months of age, whereas in the former patients occlusion of deciduous teeth had been corrected in many cases.

The number of canine cross-bites also seems to be reduced to a certain extent. However, alveolar closure with Burian flaps (consisting of a small mucoperiosteal flap and a larger vestibular mucosal flap) at the time of lip closure seems to affect canine position. Burian flaps were utilized in about half of the present cases of unilateral as well as bilateral clefts. Each one of these patients shows a canine cross-bite. Therefore, this particular variation of procedure was abandoned a few years ago.

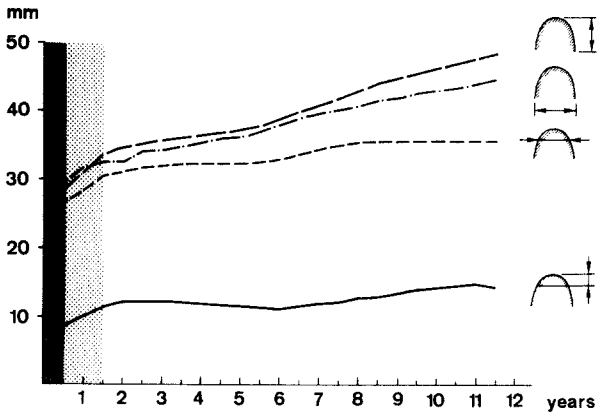

Fig. 21. Growth curves for normal upper jaws. Mean values from cases reported by Sillman.[24] Note the steepness of curves over the period of the first 6 months (dark stippled area) and 18 months (light stippled area), respectively. Longitudinal cast analysis in our cleft cases shows comparable increments.

Summarizing, it can be said that occlusion in 5-year-old patients with clefts is at present much better than it ever was in Zürich. This result was obtained despite a considerable reduction in active treatment (no retention or expansion in deciduous dentition after velar closure).

Speech results*

Speech development being influenced by an incalculable number of variables, we confine ourselves at the present time to drawing empirical comparisons from clinical observation of former and present groups. Disturbances in speech proficiency are definitely less severe today; glottal stops in particular are less frequent. Pharyngeal substitution still occurs, but is more susceptible to treatment. Speech development is not relevantly affected during its most important phase by two-stage palatal closure, but the present surgical approach regularly results in good velar length and mobility. Cineradiographic assessment demonstrates adequate velopharyngeal competency. Detailed evaluation of speech results in connection with hearing capacity is under way.

Discussion

The procedure described is based on the fact that growth potential in patients with clefts is similar to that in normal subjects. With regard to the considerable rate of growth during the first 6 months of life, total body weight being normally doubled, it seems reasonable "to take advantage of the quite dramatic rate of maxillary growth"[5] within that time and not interfere with it. It is astonishing how even structures alarmingly deficient at birth are able to catch up considerably within this early period, if they are allowed to develop freely (Figs. 11 and 20). During eruption of deciduous dentition, growth increments,

*Speech assessments by Mrs. H. Nussbaumer, clinical speech pathologist, director of Sprachheilschule Unterägeri.

although less spectacular, are still larger pro rata temporis than ever in later development (Fig. 21). Within this period inhibiting effects on growth can be minimized by careful, limited, and adequately timed surgery. Furthermore, delay of surgery permits guidance of maxillary development by early orthopedic treatment. In unilateral cases, spontaneous shifting of segments and arch alignment are induced by appropriately grinding the plate (Figs. 4, 6, and 11) in order to keep enough space between the segments for further increments. We do not primarily aim at obtaining a butt joint. Preoperative narrowing of the cleft is obviously a consequence of growth, while upper arch width is not diminishing and a favorable relationship to the fast-developing mandible is established. With correct handling of appliances, ulcerations (as imputed to them by Johnson[11]) do not occur.

In expansion cases the tuberal region is hardly influenced since fan-screws only are utilized. Interference with speech development, as assumed by Subtelny,[26] does not take place, nor does inhibited maxillary collapse have a detrimental effect on repair of the velopharyngeal mechanism as suggested by Swoiskin.[27] On the contrary, keeping the tongue out of the cleft allows narrowing of the hard palate cleft, and appropriate adjustments of the plate also permit velar tissues to develop. Veloplasty as described in this paper is actually facilitated.

As a consequence of less traumatic techniques and timing so as to spare the bony palatal shelves in favor of growth, occlusion in most cases remains regular and stable. Local irregularities were observed in both unilateral and bilateral cases when auxiliary surgical measures were used (e.g., Burian flaps, now abandoned). We have observed that even slight variations in surgical handling can be crucial. Concerning initial severity and variables *within* the patient, i.e., underlying growth patterns (skeletal Class I, II, or III or open bite), we fully agree with Pruzansky[21] that they are prognostically of major importance. It is our experience, however, that development greatly varies according to type and timing of intervention.

Cephalometric analysis in our 5-year-old patients with surgically treated complete uni- and bilateral clefts shows to date that maxillary growth disturbances, always present in former samples, can be minimized. Given the extensive variability of factors involved, we have to dispense with sophisticated statistical evaluations for the time being. A common feature always apparent is a relatively retral posture of the whole maxillomandibular complex, as described by several authors. Intermaxillary relationship is generally good in the present sample. The formerly common palatal tilting of alveolar processes and tooth germs is no longer observed and anterior cross-bites are practically nonexistent. In a transverse dimension, the soft borders of the plate give way to spontaneous development. Delay and a two-stage approach to palatal surgery minimize the amount and influence of palatal scar tissue and also result in a higher palatal vault.

In Europe, where languages change with the relatively close frontiers, speech results cannot be easily compared. In Switzerland, with 6 million inhabitants, we have four official languages. In our group of patients with two-stage palatal closure, speech development is not relevantly affected during its most important

phase even though the hard palate cleft remains open until the sixth to eighth year of age. Careful coaching of parents and child, right from the start and later during the joint orthodontic-logopedic sessions, greatly facilitates progress. No major difficulties arise which could not be overcome by speech therapy.

Conclusion

In the light of temporary results concerning maxillary growth and speech development in our cases of cleft lip and palate, we can to date only sustain the claim that coordination and judicious timing of procedures are absolute necessities in treatment. Lip repair in connection with pre- and postoperative orthopedic care results in good arch alignment and good occlusion in the early mixed dentition. Two-step closure of the palate, with postponement of the surgical intervention on the hard palate, results in better maxillary development and adequate velopharyngeal competence. The main objectives of our efforts are: (1) to normalize form and function in early infancy; (2) to permit growth to develop its full potential with regard to functional and esthetic requirements; (3) to render regular orthodontic treatment in the permanent dentition easier and successful in order to avoid large prosthetic reconstruction and/or major secondary surgery.

The mixed dentition state in several older patients treated according to the principles mentioned allows us to assume that these goals can actually be attained. The moderate increase in treatment intensity and cost during the early period will be more than outweighed by considerable alleviation later with regard to both psychological and socioeconomic factors.

REFERENCES

1. Aduss, H.: Craniofacial growth in complete unilateral cleft lip and palate, Angle Orthod. **41**: 202-213, 1971.
2. Braithwaite, F., and Maurice, J. G.: The importance of the levator palati muscle in cleft palate closure, Br. J. Plast. Surg. **21**: 60-62, 1968.
3. Čelešnik, F.: Notre procédé de traitement chirurgical du bec-de-lièvre bilatéral total, Rev. Stomatol. **63**: 386-388, 1962.
4. Crickelair, G. F.: Why repair a cleft lip? Cleft Palate J. **6**: 93-107, 1969.
5. Cronin, T. D., and Penoff, J. H.: Bilateral clefts of the primary palate, Cleft Palate J. **8**: 349-363, 1971.
6. Grob, M.: Surgery of preoperatively treated cleft lips and palates. *In* Hotz, R., editor: Early Treatment of Cleft Lip and Palate, Symposium Zürich 1964, Berne, 1964, Huber & Company, pp. 90-94.
7. Hotz, M.: Pre- and early postoperative growth-guidance in cleft lip and palate cases by maxillary orthopedics, Cleft Palate J. **6**: 361-372, 1969.
8. Hotz, M.: Aims and possibilities of pre- and postsurgical orthopedic treatment in uni- and bilateral clefts, Trans. Eur. Orthod. Soc. 553-558, 1973.
9. Hotz, M., and Perko, M.: Early management of bilateral total cleft lip and palate, Scand. J. Plast. Reconstr. Surg. **8**: 104-108, 1974.
10. Huddart, A. G.: An evaluation of pre-surgical treatment, Br. J. Orthod. **1**: 21-25, 1973.
11. Johnson, J. S.: Symposium on the early treatment of cleft lip and palate: the present dilemma, Br. J. Orthod. **1**: 11-14, 1973.
12. Kremenak, C. R., Jr., and Searls, J.: Experimental manipulation of midfacial growth, J. Dent. Res. **50**: 1488-1491, 1971.
13. Kriens, O. B.: An anatomical approach to veloplasty, Plast. Reconstr. Surg. **43**: 29-41, 1969.

14. Maisels, D. O.: The influence of pre-surgical orthodontic treatment upon surgery of cleft lip and palate, Br. J. Orthod. **1**: 15-20, 1973.
15. McNeil, C. K.: Orthopaedic principles in the treatment of lip and palate clefts. *In* Early Treatment of Cleft Lip and Palate, Hotz, R., editor: Symposium Zürich 1964, Berne, 1964, Huber & Company, pp. 59-67.
16. Narula, J. K., and Ross, R. B.: Facial growth in children with complete bilateral cleft lip and palate, Cleft Palate J. **7**: 239-248, 1970.
17. O'Donnell, J. P., Krischer, J. P., and Shiere, F. R.: Analysis of presurgical orthopedics in treatment of unilateral cleft lip and palate, Cleft Palate J. **11**: 374-393, 1974.
18. Perko, M.: Primary closure of the cleft palate using a palatal mucosal flap. An attempt to prevent growth impairment, J. Max.-Fac. Surg. **2**: 40-43, 1974.
19. Pruzansky, S.: Pre-surgical orthopedics and bone grafting for infants with cleft lip and palate: A dissent, Cleft Palate J. **1**: 164-187, 1964.
20. Pruzansky, S., and Aduss, H.: Arch form and the deciduous occlusion in complete unilateral clefts, Cleft Palate J. **1**: 411-418, 1964.
21. Pruzansky, S.: Monitoring growth of the infant with cleft lip and palate, Trans. Eur. Orthod. Soc., pp. 538-546, 1973.
22. Robertson, N. R. E.: Deciduous occlusion in children with repaired complete clefts of the lip and palate, Br. J. Orthod. **1**: 5-10, 1973.
23. Ruding, R.: Cleft palate. Anatomic and surgical considerations, Plast. Reconstr. Surg. **33**: 132-147, 1964.
24. Sillman, J. G.: Serial study of good occlusion from birth to 12 years of age, AM. J. ORTHOD. **37**: 481-507, 1951.
25. Simmen, E.: Die Morphologie der Lippen-Kiefer-Gaumenspalten im Fernröntgenbild. Eine vergleichende Untersuchung an 5-jährigen Kindern mit und ohne Lippen-Kiefer-Gaumenspalten, Med. Diss. Zürich, 1973.
26. Subtelny, J. D.: Orthodontic treatment of cleft lip and palate. Birth to adulthood, Angle Orthod. **36**: 273-292, 1966.
27. Swoiskin, L.: *In* Rosenstein, S. W.: Early orthodontic procedures for cleft lip and palate individuals: discussion, Angle Orthod. **33**: 135-136, 1963.
28. Widmaier, W.: A surgery procedure for the closure of palatal clefts. *In* Schuchardt, K., editor: Treatment of Patients with Clefts of Lip, Alveolus and Palate, Int. Symposium Hamburg 1964, Leipzig, 1966, Georg Thieme Verlag, pp. 87-89.

Plattenstrasse 11 (8028)