

Intraoral Digital Impression Technique for a Neonate With Bilateral Cleft Lip and Palate

The Cleft Palate-Craniofacial Journal
2019, Vol. 56(8) 1120-1123
© 2019, American Cleft Palate-
Craniofacial Association
Article reuse guidelines:
sagepub.com/journals-permissions
DOI: 10.1177/1055665619835082
journals.sagepub.com/home/cpc



Jilen Patel, BSc (Hons), DClinDent (Paed Dent), MRACDS, FADI, FICD^{1,2},
John Winters, BSc, MSc, MRACDS (Paed), FICD²,
and Mark Walters, BSc (Hons), MSc (Research)³

Abstract

Objective: Dental casts are an important aspect in the treatment planning, documentation, and analysis of the dental arch forms of infants with cleft lip and palate (CLP). Impression taking in a neonate is a technique-sensitive procedure, which can result in foreign body dislodgement and carries a small risk of aspiration and airway obstruction. The advent of digital dental technologies and intraoral scanning may facilitate safer, more effective, and accurate impressions for CLP infants.

Design: A digital intraoral scan of a 3-month-old with bilateral CLP (BCLP) was compared with a conventional alginate impression taken prior to primary lip repair.

Setting: Princess Margaret Hospital for Children.

Main Outcome Measures: To test the applicability and accuracy of digital impression taking for a neonate with BCLP and palate using digital morphometrics.

Results: The average deviation of points ranged above and below the plane of superimposition from +0.78 mm to -0.42 mm with a maximum range of +2.80 mm to -2.80 mm and standard deviation of 0.88 mm. The premaxillary segment showed the greatest degree of variation.

Conclusions: This is to our knowledge the first report that illustrates the use of a digital impression system to scan the oral structures of a neonate with BCLP. Digital scanning was found to be fast, accurate, and safe, when compared to a conventional alginate impression technique.

Keywords

digital, impression, scan, trios, cleft lip and palate, neonate

Background

Digital intraoral scanners for dentistry were first introduced in the 1980s. Since then, advancements in dental technologies and digital workflow have popularized the use of intraoral optical range finding scanning devices. Digital impressions confer several advantages including:

- Simplification of the impression taking process because the use of impression trays, impression material, and plaster models are no longer required. Furthermore, digital impressions eliminate the technical issues of standardizing mixing and setting times.
- Improved accuracy because digital impressions are not subject to material shrinkage, distortion, voids, or problems with insufficient material. Digital

impression systems have similar precision and greater reproducibility when compared with conventional techniques in recording dental hard tissues (Ender and Mehl, 2011; Güth et al., 2013; Seelbach et al.,

¹ UWA Dental School, The University of Western Australia, Nedlands, Western Australia, Australia

² Paediatric Dentistry, Department of Dental Medicine, Perth Children's Hospital, Nedlands, Western Australia, Australia

³ Cleft Lip and Palate Unit, Perth Children's Hospital, Nedlands, Western Australia, Australia

Corresponding Author:

Jilen Patel, UWA Dental School, The University of Western Australia, 17 Monash Avenue, Nedlands, Western Australia 6009, Australia.

Email: jilen.patel@uwa.edu.au

2013). However, further research is required to elucidate the effectiveness of these systems in recording and capturing soft tissues and edentulous arches.

- Increased reproducibility in longitudinal evaluations of the outcomes of cleft care as well as improved self-reported patient and parent/caregiver outcomes around comfort and time taken when using digital impressions compared with conventional impressions (Chalmers et al., 2016).

The rehabilitation of a child with cleft lip and palate (CLP) begins at birth and an oral impression is often one of the first procedures undertaken, to provide initial documentation of the cleft and arch form and/or for the fabrication of an oral appliance. Conventional impression taking on a neonate is a technique-sensitive procedure and carries an elevated risk compared to procedures undertaken in older infants. Complications such as foreign body dislodgement, aspiration, and airway obstruction may occur, and appropriate precautions should be taken during the procedure. The advent of digital dental technologies and intraoral optical range finding scanning may facilitate safer, more effective, and accurate impressions for infants with CLP. These technologies present the opportunity to create a digital workflow that could be employed in the diagnostic workup, treatment planning, and even fabrication of oral appliances in the management of children with clefts. This report documents the innovative use of a digital impression technique to assess arch form in an infant with bilateral CLP.

Case Description

A baby boy with an antenatal diagnosis of bilateral CLP was assessed soon after birth by the cleft and craniofacial team at the Princess Margaret Hospital for Children. At this stage, conventional alginate impressions were taken for the fabrication of an oral appliance as part of presurgical orthopedic therapy (PSO). Presurgical orthopedic therapy in the form of a passive oral appliance along with extraoral traction in the form of a bonnet and strapping was used from birth to pre-lip surgery. The child was otherwise fit and healthy. At 3 months of age, the child had pre-lip surgery impressions taken, however, due to slow weight gain, surgery was delayed. Two weeks later, the child presented for review, and after discussion and informed consent from the parents, a digital impression was taken.

Intraoral Scanning Procedure

One clinician used 2 dental mirrors to retract the buccal mucosa while a second clinician performed the digital impression. The Trios (3Shape Dental Systems, Copenhagen, Denmark) was used to scan the maxillary arch systematically from one tuberosity to the other. The palate and cleft area was subsequently scanned utilizing the existing alveolar arch landmarks. The time taken for the digital impression was just over 1 minute.

The study model created from the previous alginate impression, taken 2 weeks earlier, was also scanned using the Trios system as a reference for comparison.

Analysis of Study Models

The direct oral scan, and the scan of the previously created stone cast, were both exported as stereolithography files. Geomagic Qualify v12 (Raindrop Geomagic Inc, Research Triangle Park, North Carolina) was used to superimpose the 2 scans using a regional iterative closest point algorithm and the best-fit alignment module. Initial superimposition found the greatest variation to occur in the premaxillary segment, so for further analysis, the premaxilla from each model was selected separately and superimposed.

Results

A regional iterative closest point algorithm was used to superimpose the 2 scans based on the alveolar segments and palatal raphe. Summary distances between the 2 scans were thereby calculated. The average deviation of points ranged above and below the plane of superimposition from +0.78 mm to -0.42 mm with a maximum range of +2.80 mm to -2.80 mm and standard deviation of 0.88 mm. The premaxillary segment showed the greatest degree of variation. When this segment was isolated from the 2 scans and superimposed, the average deviation of points ranged from +0.46 mm to -0.40 mm with a range of +1.12 mm to -1.12 mm and standard deviation of 0.48 mm.

Discussion

This report describes an innovative approach to oral impression taking in a neonate with bilateral CLP. Furthermore, when combined with digital morphometrics, it creates a unique opportunity to compare both conventional and digital impression techniques in the same infant.

The rehabilitation of a child with CLP begins at birth. Many centers advocate for the use of early interventions ranging from feeding appliances to PSO. There remains ongoing debate as to the efficacy of presurgical intervention in the management of CLP. Aspects such as cost-benefit of treatment and the influence of PSO treatment on facial growth and arch form in the longer term remain controversial with the current evidence being of low quality to make any conclusive recommendations (Uzel and Alparslan, 2011; Hosseini et al., 2017). Although further high-quality studies are required, there is an emerging body of evidence that have highlighted promising results from the use of techniques such as nasoalveolar molding (Spengler et al., 2006; Abbott and Meara, 2012). These therapies all require an oral impression to be taken. Conventional impression taking in an infant with CLP is technique-sensitive. This is particularly true if an appliance is to be made. Infants born with bilateral CLP commonly present with protrusion and deviation of the premaxilla, underdevelopment of the columella, and

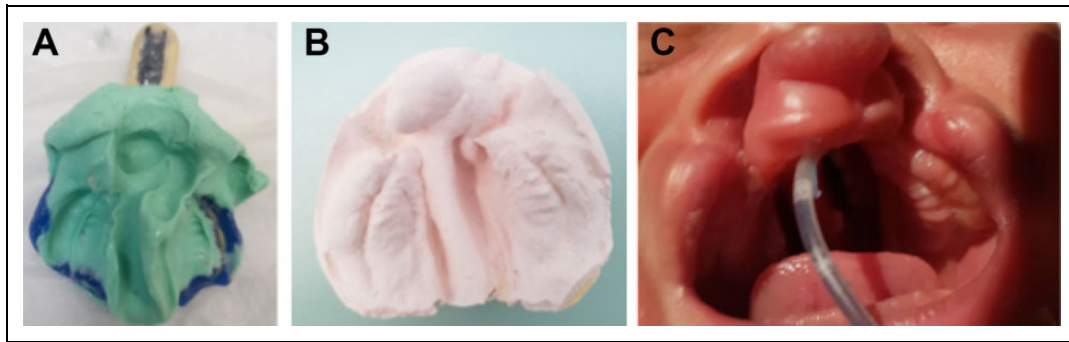


Figure 1. Impression taking can often be complicated by the limited opening, visibility, and the presence of orogastric tubes in neonates with clefts. (A) Alginate impression taken at birth showing the protruded and deviated premaxillary segment and the need for adequate material and support to capture the peripheral anatomy, (B) stone model, (C) view of the cleft at birth.

distortion of the maxillary lateral alveolar segments. These factors create significant challenges in achieving an accurate oral impression (Figure 1). The impression should record the peripheral extensions of both buccal and premaxillary cleft segments, the mucobuccal fold, and adequately extend into the cleft area (Jacobson and Rosenstein, 1984). As conventional impression taking in a neonate is technique-sensitive and carries a small risk of airway obstruction, appropriate precautions must be taken during the process. An irreversible hydrocolloid such as alginate or a rapid setting polyvinyl siloxane can provide an accurate record of the oral structures including the undercut areas. Control of the impression material is difficult, and there is the potential for impression material to be pushed too deep into the nasal cavity, distally through the pharynx, or into undercuts in the nasopharyngeal region. A relatively stiff mix of alginate impression material and the use of a custom-made perforated impression tray have been recommended when taking impressions in infants with orofacial clefts. Digitization of oral casts can provide accurate and reliable 3-dimensional (3D) examination of arch morphology (Berkowitz, 1999; Braumann et al., 2002; Brief et al., 2006; Oosterkamp et al., 2006).

The Trios 3Shape intraoral digital impression system became commercially available in 2011 using the principle of ultrafast optical sectioning and confocal microscopy. The system recognizes variations in the focus plane of the pattern over a range of focal plane positions, while maintaining a fixed spatial relation between the scanner and the object being scanned (Ting-Shu and Jian, 2015). This concept of range finding as a means of defining a surface manifold is the basis of the Trios system. Furthermore, a scanning speed of up to 3000 images per second reduces the influence of movement between the scanning probe and the oral structures. By analyzing a large number of images of the surface topography, the system can rapidly create a final digital 3D model to reflect the configuration of teeth and arch form. In addition, color information can be texture mapped onto the 3D surface manifold generating a realistic 3D image that is easy for patients and their families to understand. The digital superimposition shown in Figure 2 suggests that a digital impression technique can accurately

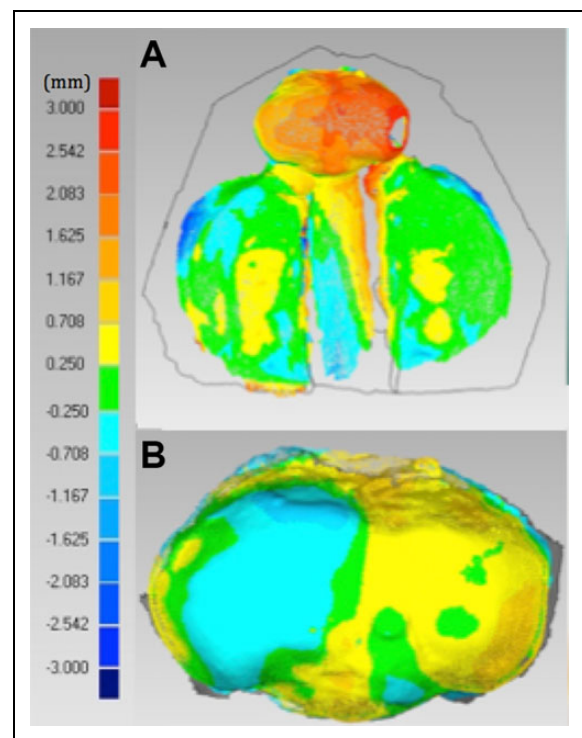


Figure 2. Digital superimposition of the direct oral scan, and the scan of the previously created stone cast. (A) superimposition showing minimal differences in the cleft segments and palatal shelves. The greatest variation, of between 2 and 3 mm, is seen in the premaxillary segment which had been aligned using the presurgical orthopedic treatment in preparation for primary cleft surgery; (B) superimposition of the premaxillary segments in isolation showing minimal variation confirming that the premaxilla had not changed size or shape but had been successfully manipulated into a more favorable position.

capture the cleft anatomy. Although the impressions were taken 2 weeks apart, the main difference between the 2 impression techniques is seen in premaxillary region. This difference is attributed to physical distortion from the pressure placed on this segment when a conventional impression technique is used. In comparison, a digital scan places no pressure on the alveolus or other tissues and can better capture the static morphology of the oral structures.

Intraoral scanners and the proprietary existing software are not designed to record cleft anatomy and are primarily designed for use in adults to capture the form of the complete dental arch and dentition. The scanner tip is relatively large and can be challenging to negotiate with the oral cavity of a neonate. Furthermore, the software has been tailored to capture a contiguous dental arch and remove spurious scanned surfaces. In respect to scanning infants with CLP presenting with a discontinuous alveolus, the algorithms imbedded within the software when processing scan data can interpret components of the discontinuous segments as spurious scanned surfaces and remove some of the desirable detail. In the case reported herein, the premaxillary segment was retroclined and the cleft width reduced following PSO treatment sufficiently for the algorithms to capture the dental alveolar arch as a contiguous surface.

We are currently exploring scanning techniques and post-capture imaging manipulation using the Trios scanner to facilitate capture the form of the dental alveolar segments in infants with facial clefts. Without prior knowledge of the operatives and limitations in the algorithm(s) used in the proprietary software, this exercise is a matter of “trial and error.” It is evident from this preliminary work is some cleft infants do prove difficult to capture complete segments of the dental-alveolar arch where others do not. It may not be just a function of cleft width, line of sight, and the ability for the scanner tip to be positioned perpendicular to the desired surface are also likely contributing factors to incomplete capture outcomes. We will report on these explorations and digital workups using scan data in due course.

Conclusion

This case study reports the use of a digital impression system in simplifying oral impression procedures for a neonate with CLP. The digital scan was found to be fast, accurate, and safe, when compared with a conventional alginate impression technique. Intraoral optical range finding technologies and digital workflows may open new avenues in the treatment planning and management of children with clefts.

Acknowledgments

The authors would like to acknowledge Mr David Owen for his support and assistance in the acquisition and 3D printing of the models in this study.

Declaration of Conflicting Interests

The author(s) declared no potential conflicts of interest with respect to the research, authorship, and/or publication of this article.

Funding

The author(s) received no financial support for the research, authorship, and/or publication of this article.

ORCID iD

Jilen Patel  <https://orcid.org/0000-0002-8698-4965>

References

- Abbott MM, Meara JG. Nasoalveolar molding in cleft care: is it efficacious? *Plast Reconstr Surg*. 2012;130(3):659-666. doi:10.1097/PRS.0b013e31825dc10a.
- Berkowitz S. A multicenter retrospective 3D study of serial complete unilateral cleft lip and palate and complete bilateral cleft lip and palate casts to evaluate treatment: part 1—the participating institutions and research aims. *Cleft Palate Craniofac J*. 1999;36(5):413-424.
- Braumann B, Keilig L, Bourauel C, Jäger A. Three-dimensional analysis of morphological changes in the maxilla of patients with cleft lip and palate. *Cleft Palate Craniofac J*. 2002;39(1):1-11.
- Brief J, Behle JH, Stellzig-Eisenhauer A, Hassfeld S. Precision of landmark positioning on digitized models from patients with cleft lip and palate. *Cleft Palate Craniofac J*. 2006;43(2):168-173.
- Chalmers EV, McIntyre GT, Wang W, Gillgrass T, Martin CB, Mossey PA. Intraoral 3D scanning or dental impressions for the assessment of dental arch relationships in cleft care: which is superior? *The Cleft Palate Craniofac J*. 2016;53(5):568-577.
- Ender A, Mehl A. Full arch scans: conventional versus digital impressions—an in-vitro study. *Int J Comput Dent*. 2011;14(1):11-21.
- Güth JF, Keul C, Stimmelmayer M, Beuer F, Edelhoff D. Accuracy of digital models obtained by direct and indirect data capturing. *Clin Oral Investig*. 2013;17(4):1201-1208. doi:10.1007/s00784-012-0795-0.
- Hosseini HR, Kaklamanos EG, Athanasiou AE. Treatment outcomes of pre-surgical infant orthopedics in patients with non-syndromic cleft lip and/or palate: a systematic review and meta-analysis of randomized controlled trials. *PLoS One*. 2017;12(7):e0181768. doi:10.1371/journal.pone.0181768.
- Jacobson BN, Rosenstein SW. Early maxillary orthopedics for the newborn cleft lip and palate patient: an impression and an appliance. *Angle Orthod*. 1984;54(3):247-263.
- Oosterkamp BCM, van der Meer WJ, Rutenfrans M, Dijkstra PU. Reliability of linear measurements on a virtual bilateral cleft lip and palate model. *Cleft Palate Craniofac J*. 2006;43(5):519-523.
- Seelbach P, Brueckel C, Wöstmann B. Accuracy of digital and conventional impression techniques and workflow. *Clin Oral Investig*. 2013;17(7):1759-1764. doi:10.1007/s00784-012-0864-4.
- Spengler AL, Chavarria C, Teichgraber JF, Gateno J, Xia JJ. Pre-surgical nasoalveolar molding therapy for the treatment of bilateral cleft lip and palate: a preliminary study. *Cleft Palate Craniofac J*. 2006;43(3):321-328. doi:10.1597/05-093.1.
- Ting-Shu S, Jian S. Intraoral digital impression technique: a review. *J Prosthodont*. 2015;24(4):313-321.
- Uzel A, Alparslan ZN. Long-term effects of presurgical infant orthopedics in patients with cleft lip and palate: a systematic review. *Cleft Palate Craniofac J*. 2011;48(5):587-595. doi:10.1597/10-008.