

# Ectopic eruption of the first permanent molars: Prevalence and etiologic factors

Kanoknart Chintakanon, DDS, MDS-Orthodontics (Adelaide);  
Patipat Boonpinon, DDS

**E**ctopic eruption of the first permanent molars is a local disturbance characterized by eruption of these teeth under the distal undercut of the second primary molars and failure of the first permanent molars to erupt to the normal occlusal plane. This abnormality can be classified into reversible and irreversible types.<sup>1</sup> The prevalence of ectopic eruption of the maxillary first permanent molars varies from 1.8% to 6% in normal populations<sup>2-7</sup> and more than 4 times that in children with clefts.<sup>8,9</sup> Bjerklin and Kuroi<sup>10</sup> suggested that the difference in these rates could be due to the group size, caries status, or age range of the population studied. A significant familial tendency for ectopic eruption has also been reported.<sup>11</sup> The prevalence of this abnormality has not been found to differ among white, black, Hispanic, and Asian ethnic groups.<sup>7</sup>

Possible etiologic factors for this phenomenon are: small maxilla,<sup>4,12</sup> posteriorly positioned maxilla relative to cranial base,<sup>4</sup> path of eruption of

the maxillary first permanent molar,<sup>4,12,13</sup> premature eruption of this tooth with inadequate anterior movement of deciduous dentition,<sup>12</sup> mesiodistal widths of the maxillary first and second primary molars,<sup>4,13</sup> asynchronization between eruption of the maxillary first permanent molar and tuberosity growth,<sup>14</sup> and retarded calcification and eruption of the dentition.<sup>4</sup> Genetic influence on a multifactorial basis is also postulated.<sup>11</sup>

Except for a few case reports and anecdotal comments,<sup>1,15-19</sup> the prevalence and etiology of ectopic eruption of the mandibular first permanent molars have not been reported.

The purpose of this research was to study the prevalence of ectopic eruption of the maxillary and mandibular first permanent molars, and possible etiologic factors contributing to the ectopic eruption. The study was also designed to test whether high proximal caries status reduced the prevalence of ectopic eruption.

## Abstract

The purpose of this research was to study the prevalence of ectopic eruption of the first permanent molars and possible etiologic factors. A group of 4,232 Thai students, from 6 to 9 years old, was examined. The prevalence of ectopic eruption of the first permanent molars in the subjects was 0.75%. Both the severity of the ectopic eruption and the amount of root resorption on the second primary molars were more pronounced in the maxilla than in the mandible. The important etiologic factors were the eruption path of the first permanent molars relative to reference lines and the size of the mandibular second primary molars. The amount of proximal caries did not seem to affect the prevalence of ectopic eruption.

## Key words

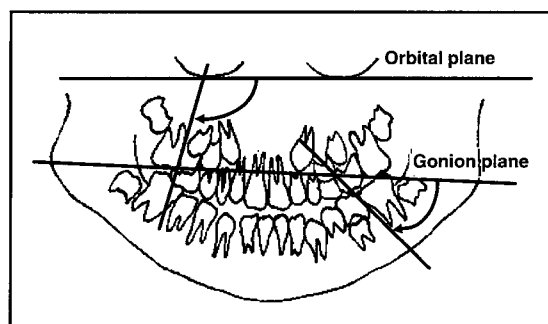
Ectopic eruption • Prevalence • First permanent molar • Mixed dentition • Longitudinal study

Submitted: April 1997

Revised and accepted: July 1997

Angle Orthod 1998;68(2):153-160.

**Figure 1**  
Method of measuring mesial angulation of maxillary first permanent molars relative to orbital line and mesial angulation of mandibular first permanent molars relative to gonion line.



**Figure 1**

**Materials and methods**

**Prevalence study**

A group of 4,232 northern Thai children between 6 and 9 years old from 19 schools was examined clinically. Children were included in the study only if their permanent molars were present and erupted, leaving a sample of 3,612.

The caries status of each subject was recorded. Mesial and distal sides of each tooth were scored according to the following scale:

- 0 no caries
- 1 proximal cavitation not extending as far as the width of the marginal ridge
- 2 proximal cavitation extending beyond the width of the marginal ridge
- 3 retained root or missing tooth

Socioeconomic status has been associated with caries prevalence in at least one report.<sup>20</sup> In the present study, schools were grouped by socioeconomic status so that the prevalence of ectopic eruption among populations with low, moderate, and high levels of caries could be compared.

**Etiology study**

Children with at least one ectopically erupted first permanent molar were selected as experimental subjects. Thirty children with normal occlusion and without dental caries were selected as controls. History and clinical examination, study models, intra- and extraoral photographs, lateral cephalograms, orthopantomograms, and periapical radiographs of the affected teeth were taken. The experimental group was observed yearly for 3 years.

**Measurements and analyses**

Subjective symptoms such as pain or discomfort of the affected teeth were recorded. Mobility of the second primary molar was based on Miller's mobility index.<sup>21</sup>

The mesiodistal width of all the first permanent molars and all the second primary molars was measured on study models to an accuracy of 0.1 mm with a dental Vernier, using the method described by Moorrees and Reed.<sup>22</sup> The width of the ectopic first permanent molars was measured

after the tooth was fully erupted, either by treatment or by the exfoliation of the second primary molars. The type of occlusion was recorded using the relationship between the distal proximal surface of the maxillary and mandibular second primary molars (Baume's classification).<sup>23</sup> The method used to classify the severity of ectopic eruption, using the width of the marginal ridge of the first permanent molar, was adapted from Harrison and Michal<sup>24</sup> as follows:

- 0 normal or no sign of impaction
- 1 minimal lock or impacted less than half the width of the distal marginal ridge
- 2 moderate lock or impacted more than half the width of the distal marginal ridge but less than the width of the distal marginal ridge
- 3 severe lock or impacted more than the width of the distal marginal ridge

Orthopantomograms were used to classify the degree of root resorption of the second primary molars and to measure the mesial angulation of the first permanent molars. The degree of root resorption was classified as follows:-

- 0 no root resorption
- 1 minor resorption of the root involving less than half the dentine thickness
- 2 moderate resorption of the root involving more than half the dentine thickness but no pulpal involvement
- 3 severe resorption with pulpal involvement

The method for measuring the mesial angulation of the maxillary first permanent molars using the infraorbital reference line described by Bjerklin and Kuroi<sup>13</sup> was used. The gonion reference line adapted from frontal cephalometric analysis was used for measuring the mesial angulation of the mandibular first permanent molars (Figure 1). The mesial vertical line was drawn from the mesial tangent of the crown and the mesial part of the mesiobuccal root of the maxillary molar or the mesial root of the mandibular molar. The mesial angle was measured to the nearest 0.5 degrees.

Angular measurements, including SNA, SNB, ANB and soft tissue facial convexity, were measured on lateral cephalograms. Linear measurements included maxillary length (ANS-PNS) and mandibular length (Co-Pg). The precision of measurement was 0.5 degrees for angles and 0.5 mm for distances. Linear measurements were recorded directly from the cephalogram without magnification correction.

Chi-square tests were used to analyze the differences in the prevalence of ectopic eruption between males and females, between the right side and the left side of the mouth, and between

**Table 1**  
**Distribution of ectopic eruption in males and females**

	Subjects	Ectopic eruption	
	N	N	%
Male	2,481	20	0.81
Female	1,131	7	0.62
Total	3,612	27	0.75

$\chi^2$ -test for sex differences:  $p > 0.05$

**Table 2**  
**Number of maxillary second primary molars distributed by caries status and ectopic eruption of maxillary permanent first molars in different school groups**

	Private school		Public school		Municipal school	
	%	N	%	N	%	N
No caries	64.0	2572	58.1	1072	58.3	789
Cavitation < marginal ridge	16.5	665	19.9	367	18.5	251
Cavitation > marginal ridge/ tooth loss	19.5	787	22.0	407	23.2	314
Ectopic eruption	0.39	8	0.32	3	0.44	3

$\chi^2$ -test for caries status:  $p < 0.05$ ,  $\chi^2$ -test for ectopic eruption:  $p > 0.05$

**Table 3**  
**Distribution of ectopic eruption**

	Unilateral	Unilateral	Bilateral	Total
	(left)	(right)		
Maxilla	3	5	3	11
Mandible	3	3	6	12

**Table 4**  
**Mobility of second primary molars**

	Mobile teeth		Nonmobile teeth	
	N	%	N	%
Maxilla	3	21.4	11	78.6
Mandible	0	0	18	100

various school groups according to caries status. Analysis of variance and Student's *t*-tests were used to analyze tooth size and the orthopantomographic and cephalometric measurements between the ectopic eruption and control groups. Student's *t*-tests were also used in the method error study.

**Errors of the method**

Orthopantomograms and lateral cephalograms were taken by the same radiologist using the same machine. Each measurement was taken by the same operator and duplicated a few weeks later for double determination of the error of the method. Although angular measurement errors in the orthopantomogram measurements were found to be greater than cephalometric measurements, all errors were found to be small and acceptable.

**Results**

**Prevalence study**

Of the 3,612 children in the sample, 27 were found to have ectopic eruptions, for a prevalence rate of 0.75%. Maxillary first permanent molars were involved in 14 children (0.39%) and mandibular first permanent molars were involved in 13 (0.36%). Although the prevalence of ectopic

eruption was found to be higher in males than in females, the difference was not statistically significant (Table 1).

Schools were grouped into three categories based on socioeconomic status, i.e., high for private schools, moderate for public schools, and low for municipal schools. The proportion of children selected from each school group in this study was similar to the proportion of children from each school type in the population of the area. Caries rates were very high, with 94% of the sample affected. Chi-square tests revealed that caries prevalence was significantly different among school groups ( $p < 0.05$ ).

The maxillary dentition was selected as a model to test the prevalence of ectopic eruption in a different group of subjects that had different caries status. In the population studied, 94% had caries and 40% of these had caries of the maxillary second primary molars. Table 2 shows the distribution of caries in the maxillary second primary molars and ectopic eruption of the maxillary first permanent molars in different school groups. Although Chi-square tests revealed that the amount of proximal caries and/or loss of maxillary second primary molars differed significantly among school groups ( $p <$

Severity	Maxilla		Mandible	
	N	%	N	%
Minimal lock	0	0	11	61.1
Moderate lock	2	14.3	5	27.8
Severe lock	12	85.7	2	1.1
Total	14	100	18	100

	Maxilla		Mandible	
	Control	Ectopic	Control	Ectopic
Number of teeth	53	10	50	16
Mean (mm)	9.48±0.46	9.50±0.67	10.5±0.44	11.8±0.49
t-test	$p>0.05$		$p<0.001$	

0.001), a significant difference in the prevalence of ectopic eruption of the maxillary first permanent molars was not found.

#### **Etiology study**

Of 27 cases of ectopic eruption found in the prevalence study, four were excluded from the etiology study because two students moved away; one student was Caucasian, so might have had different craniofacial features than the population studied; and one student had a stainless steel crown on the maxillary second primary molar, precluding measurement of the natural tooth. Consequently, 23 ectopic eruption cases were included in the study. Table 3 shows the number of people with ectopic eruption in the maxilla and the mandible. There was no statistical difference in prevalence for the left, right, or both sides of the arches.

During the 3-year period of observation, two cases (6.25%) of ectopic eruption were found to be of the reversible type; both these were found in the maxilla. Resorption of the roots of the maxillary second primary molars was also found in both cases. All cases of ectopic eruption of the mandibular first permanent molars were of the irreversible type.

#### **Measurements and analyses**

None of the children with ectopic eruption reported pain or discomfort related to the abnormality. There was no sign of infection related to this abnormality even though resorption of the roots of the primary second molars was found.

Mobility of second primary molars adjacent to the ectopic eruption was found in 3 of 32 teeth. Mobility was classified as level 2, which represents movement of the teeth by about 1 mm, according to Miller's mobility index. None of the cases of ectopic eruption of mandibular first permanent molars was found to be associated with mobility of the second primary molars adjacent to the affected teeth (Table 4).

Ectopic eruption of the maxillary first permanent molars was found primarily in children with Class I occlusion, but was also found in both

Class II and III malocclusions. Ectopic eruption of the mandibular first permanent molars was also found mainly in children with Class I occlusion, but not at all in children with Class III malocclusion. However, this could be due to the low prevalence of Class III in the population.

Severity of the ectopic eruption is shown in Table 5. The majority of the ectopically erupted first permanent molars in the maxilla were found to be severe while those of the mandible were found to be minimal.

Maynard et al.<sup>25</sup> found no sex differences in the mesiodistal widths of the deciduous teeth. This study also found no differences in second primary molar mesiodistal widths between males and females, so the data were then pooled and analyzed as one group (Table 6). Analysis of variance and Student's *t*-test showed that there was no significant difference in the mesiodistal width of the maxillary second primary molars between the ectopic eruption group and the control group. However, for the ectopic eruption group, the mesiodistal width of the mandibular second primary molars was significantly larger than that of the control group ( $p<0.001$ ).

The degree of root resorption of the second primary molars adjacent to the ectopically erupted teeth is shown in Table 7. Root resorption of the second primary molars was more frequent and more severe in the maxilla than in the mandible. The crown of the ectopically erupted maxillary first permanent molars generally impacted the second primary molars at the root area, while the crown of the ectopically erupted mandibular first permanent molars impacted the crown area of the second primary molars.

The mesial angulation of the maxillary first permanent molars to the orbital plane and mesial angulation of the mandibular first permanent molars to the gonion plane were not found to be significantly different between males and females, therefore the data were pooled and analyzed as a single group. The mesial angulation of the maxillary first permanent molars to the

Degree of root resorption	0	1	2	3
Maxilla (teeth)	0	1	2	11
Mandible (teeth)	17	0	0	1

orbital plane and mesial angulation of the mandibular first permanent molars to the gonion plane are shown in Table 8. Analysis of variance and *t*-tests showed that the difference in mesial angulation of the maxillary first permanent molars to the orbital plane between the ectopic eruption group and the control group was highly significant ( $p < 0.001$ ), while the difference in mesial angulation of the mandibular first permanent molars to the gonion plane between the ectopic eruption group and the control group was minimally significant ( $p < 0.05$ ).

Because the cephalometric measurements were not found to differ significantly between males and females, the data were pooled and analyzed as a single group (Table 9). None of the lateral cephalometric measurements were found to differ significantly between the ectopic eruption group and the control group.

### Discussion

The prevalence of ectopic eruption of the maxillary first permanent molars in this study is extremely low when compared with previous studies.<sup>1-7</sup> The difference may be due to the method of diagnosis and the caries status in the population. Periapical or bitewing radiography can detect the abnormality for children as young as 4 years old.<sup>14</sup> In the present study, only clinical diagnosis was used when the first permanent molars were erupted; therefore, any abnormality of the unerupted first permanent molars could not be detected. Furthermore, because examination was performed at a later age in the present study, reversible ectopic eruptions would have been missed.

Proximal caries or loss of teeth causes arch length reduction in the primary dentition, which may affect the prevalence of the ectopic eruption of the first permanent molars. This reduction in arch length may allow the eruption of a first permanent molar that would otherwise have been ectopically erupted under the distal undercut of the second primary molar, in a more mesial position. However, the calculation for the total

	6/ to orbital plane		/6 to gonion plane	
	Control	Ectopic	Control	Ectopic
Number of teeth	60	13	60	18
Mean (degree)	106.0±8.5	82.5±6.0	46.0±7.0	41.5±9.5
<i>t</i> -test	$p < 0.001$		$p < 0.05$	

	Control		6/ ectopic eruption		/6 ectopic eruption	
	Mean	S.D.	Mean	S.D.	Mean	S.D.
SNA (deg)	81.5	3.0	81.0	4.0	82.0	3.0
SNB (deg)	76.5	2.5	77.5	3.5	78.0	3.0
ANB (deg)	4.5	1.5	3.5	1.5	4.5	1.5
Convexity (deg)	46.5	2.0	45.5	2.5	45.5	3.5
ANS-PNS (mm)	101.5	4.5	101.5	3.0	101.0	5.5
Co-Pg (mm)	142.0	8.0	145.0	5.5	142.0	6.0

amount of the reduced arch length was hard to determine accurately owing to factors such as mesial drift, inability to measure the actual size of missing tooth material, and differences in determining the initial position of the first permanent molar. As the second primary molar is closest to the first permanent molar and ectopic eruption of the first permanent molar cannot occur if the second primary molar is not present, the caries status of the second primary molars seems to be the most influential extrinsic factor that could affect the prevalence of the ectopic eruption of the first permanent molars. The influence of second primary molar status on the prevalence of the ectopic eruption of the first permanent molars was therefore investigated. Caries status in this population was very high (94%), so ectopic eruptions may be masked by reductions in primary arch length due to proximal caries or loss of teeth. However, this research failed to demonstrate a difference of prevalence of ectopic eruption among groups of children with different caries status. It is possible that the prevalence of ectopic eruption was so low that the amount of proximal caries of the maxillary second primary molars, which is not a direct etiologic factor, plays only a minor role in the prevalence of ectopic eruption.

To the best of the authors' knowledge, the prevalence of ectopic eruption of the mandibular first permanent molars has never been reported. Young<sup>1</sup> stated, without evidence, that ectopic eruption of the first permanent molars

occurred 25 times more frequently in the maxilla than in the mandible. Dixon<sup>17</sup> reported 10 cases of ectopic eruption of first permanent molars, 2 of which were in the mandible. In this study, the prevalence of ectopic eruption of the first permanent molars in the maxilla was similar to that in the mandible.

The severity of the ectopic eruption and the resorption of the roots of the second primary molars were more pronounced in the maxilla than in the mandible. This may depend on where the crown of the ectopic molar impacts the second primary molar. If the crown of the ectopic molar impacts the second primary molar at the crown, which is composed of enamel, resorption is not found. This type of contact was found in 94.5% of the ectopic eruption cases in the mandible. If the contact point is under the cemento-enamel junction, the chance for root resorption is greater. This was found for all of the ectopic eruptions in the maxilla. Kennedy and Turley<sup>26</sup> suggested that spontaneous self-correction depends on the degree of root resorption and the amount of enamel ledge of second primary molar entrapping the ectopic first permanent molar, but that did not hold true in this study. Two cases of reversible ectopic eruption of maxillary first permanent molars showed severe root resorption of the adjacent primary second molars. Thus, the degree of root resorption is not the indicator for distinguishing between reversible and irreversible types in this study. All of the abnormalities in the mandible were irreversible even though root resorption of the second primary molars was not found in most cases.

The study showed that the most important etiologic factor was the eruption path or mesial angulation of the first permanent molars relative to the chosen reference lines. Although the angle of the mesial surface of the ectopic molars relative to the reference lines was significantly

smaller than that of normally erupted molars, it was clinically relevant only for maxillary ectopic eruption. The ectopic maxillary first permanent molars had a more acute mesial angulation relative to the reference plane, while the normally erupted molars had an obtuse mesial angulation. Both the ectopically and normally erupted mandibular first permanent molars had acute mesial angulations relative to the gonion reference line. This research cannot provide the critical angle beyond which ectopic eruption may be expected. Moreover, the angle relative to the reference line can change dramatically, depending on the patient's head posture while the radiograph is taken.

The selection of reference lines on the orthopantomogram may be considered inappropriate because the angle of the mesial side of the first permanent molars referred to the anteroposterior plane while the reference lines are in the transverse plane. The method of measuring mesial angulation of the ectopic eruption of the first permanent molars was first used by Pulver<sup>4</sup> on oblique cephalograms and by Bjerklin and Kuroi<sup>13</sup> on orthopantomograms. The results from the previous studies seem to be consistent and appropriate. As an orthopantomogram is commonly used for dental examination, it was selected for use in this study. The constructed gonion line was used so that information on ectopic eruption in the mandible can be compared with that in the maxilla on the same radiograph. The construction of a gonion line is highly repeatable, because the image of the structures is not superimposed by other bony structures. Gooris et al.<sup>27</sup> and Staggers et al.<sup>28</sup> used the occlusal plane as a reference line for measuring the angle of the mandibular third molars. The occlusal plane reference line is considered to represent the anteroposterior plane, which is the same plane measured from the third molars.

However, in this study, the occlusal reference line was difficult to construct consistently due to irregularity of the occlusal plane. This was, first, because many children had lost teeth through caries, and second, because many children were in the transitional period between the primary and permanent dentition. The occlusal lines were sometimes curved or jagged rather than straight. Using the occlusal plane as the reference line seemed to produce more errors than using the gonion line.

The size of the second primary molars was another etiologic factor. However, it was found to be significant only for the ectopic eruption of the mandibular first permanent molar. Although the width of the ectopic first permanent molars was to be measured when the teeth were erupted out of the distal undercut of the second primary molars, very few patients presented for treatment. Exfoliation of the second primary molars, especially in the mandible, had not occurred in most cases during the 3 years of observation. The actual tooth size of the ectopic first permanent molars could not, therefore, be measured. Due to the small sample size, comparison of the size of the ectopic first permanent molars with the controls was considered unreliable.

Ectopically erupted mandibular molars would seem to cause few problems clinically, as the majority of the cases in this study caused no harmful consequences, such as root resorption of the second primary molars. Furthermore, the amount of impaction was generally less than the leeway space, therefore the permanent second premolar is able to erupt normally into the available space. However, the area where the ectopic eruption presented is susceptible to food impaction and is difficult to clean. Development of caries in such areas may be of concern.

## **Conclusions**

The prevalence of ectopic eruption of the first permanent molars was 0.75% in students between 6 and 9 years old. Prevalence in the maxilla was similar to that in the mandible. Most of the ectopic eruptions found were of the irreversible type. Pain, discomfort, or infection were not found in patients with ectopic eruption in this study. The severity of the ectopic eruption and the resorption of the roots of the adjacent second primary molars were more pronounced in the maxilla than in the mandible. The most important etiologic factor was the eruption path of the affected teeth relative to the reference lines. The difference in the prevalence of the ectopic eruption of the maxillary first permanent molars was not found among groups of students with different amounts of proximal caries.

## **Acknowledgments**

The authors would like to thank Professor W.J. Sampson, Dr. A.S. Cayley, and Dr. A.P. Tindall for their advice in preparing this manuscript.

## **Author Address**

Dr. Kanoknart Chintakanon  
P.O.Box 552  
Blackwood, S.A. 5051, AUSTRALIA  
Office telephone number : 08-83033102  
Home telephone number : 08-82782710  
Fax number : 08-83033444  
E-mail: kchintakanon@dentistry.adelaide.edu.au  
*Kanoknart Chintakanon, former assistant professor, Department of Orthodontics, Faculty of Dentistry, Chiang Mai University, Thailand. Currently PhD student, Department of Dentistry, The University of Adelaide, South Australia, Australia.*  
*Dr. Patipat Boonpinon, DDS, Department of General Dentistry, Faculty of Dentistry, Chiang Mai University, Thailand.*

## References

1. Young DH. Ectopic eruption of the first permanent molar. *J Dent Child* 1957;24:153-62.
2. Cheyne VD, Wessels KE. Impaction of permanent first molar with resorption and space loss in region of deciduous second molar. *J Am Dent Assoc* 1947;35:774-80.
3. O'Meara WF. Ectopic eruption pattern in selected permanent teeth. *J Dent Res* 1962;41:607-16.
4. Pulver F. The etiology and prevalence of ectopic eruption of the maxillary first permanent molar. *J Dent Child* 1968;35:138-46.
5. Bjerklin K, Kurol J. Prevalence of ectopic eruption of the maxillary first permanent molar. *Swed Dent J* 1981;5:29-34.
6. Wäckerle-Heporauta E Häufigkeit und Ausmass der beim durchbruch oberer 6-Jahrmolaren auftretenden unterminierenden resorptionen benachbarter Milchfüner (thesis). Zurich: University of Zurich 1981.
7. Kimmel NA, Gellin ME, Bohannon HM, Kaplan AL. Ectopic eruption of maxillary first permanent molars in different areas of the United States. *J Dent Child* 1982;49:294-9.
8. Carr GE, Mink JR. Ectopic eruption of the first permanent molar in cleft lip and cleft palate children. *J Dent Child* 1965;32:179-88.
9. Bjerklin K, Kurol J, Paulin G. Ectopic eruption of the maxillary first permanent molars in children with cleft lip and/or palate. *Eur J Orthod* 1993;15:535-40.
10. Kurol J, Bjerklin K. Ectopic eruption of maxillary first permanent molars: A review. *J Dent Child* 1986;53:209-14.
11. Kurol J, Bjerklin K. Ectopic eruption of maxillary first permanent molars: Familial tendencies. *J Dent Child* 1982;49:35-8.
12. Chapman MH. First permanent molars partially impacted against second deciduous molars. *Int J Oral Surg* 1923;9:339-45.
13. Bjerklin K, Kurol J. Ectopic eruption of the maxillary first permanent molar: Etiologic factors. *Am J Orthod* 1983;84:147-55.
14. Hermann E. The malposed first permanent molar. *NY State Dent J* 1969;35:343-50.
15. Lewis SJ. Ectopic eruption of permanent teeth as a factor in premature loss of deciduous teeth. *J Am Dent Assoc* 1936;23:1019-27.
16. Sweet CA. Ectopic eruption of permanent teeth. *J Am Dent Assoc* 1939;26:574-9.
17. Dixon DA. Impactions of the first permanent molar. *Br Dent J* 1959;106:281-3.
18. Duncan WK, Ashrafi MH. Ectopic eruption of the mandibular first permanent molar. *J Am Dent Assoc* 1981;102:651-4.
19. Groper JN. Ectopic eruption of a mandibular first permanent molar: report of an unusual case. *J Dent Child* 1992;59:228-30.
20. Beal JF. Social factors and preventive dentistry. In: Murray JJ, ed. *The prevention of dental disease*. Oxford: Oxford University Press, 1990:376-8.
21. Miller SC. *Oral diagnosis and treatment planning*. Philadelphia: P. Blakiston's Son & Co. 1936:7.
22. Moorrees CFA, Reed RB. Correlation among crown diameters of human teeth. *Arch Oral Biol* 1964;9:685-97.
23. Baume LJ. Physiological tooth migration and its significance for the development of occlusion. II. The biogenesis of accessional dentition. *J Dent Res* 1950;29:331-337.
24. Harrison LM, Michal BC. Treatment of ectopically erupting permanent molars. *Dent Clin North Am* 1984;28:57-61.
25. Maynard TF, Staley RN, Jakobsen JR. Deciduous tooth dimensions in unilateral cleft lip and palate subjects. *J Dent Res* 1994;73:580.
26. Kennedy DB, Turley PK. The clinical management of ectopically erupting first permanent molars. *Am J Orthod Dentofac Orthop* 1987;92:336-45.
27. Gooris CG, Artun J, Joondeph DR. Eruption of mandibular third molars after second molar extractions: A radiographic study. *Am J Orthod Dentofac Orthop* 1990;98:161-7.
28. Stagers JA, Germane N, Fortson WM. A comparison of the effects of first premolar extractions on third molar angulation. *Angle Orthod* 1992;62:135-8.