

# Increased Occurrence of Dental Anomalies Associated with Infraocclusion of Deciduous Molars

Miriam Shalish<sup>a</sup>; Sheldon Peck<sup>b</sup>; Atalia Wasserstein<sup>c</sup>; Leena Peck<sup>d</sup>

## ABSTRACT

**Objective:** To test the null hypothesis that there is no relationship between infraocclusion and the occurrence of other dental anomalies in subjects selected for clear-cut infraocclusion of one or more deciduous molars.

**Materials and Methods:** The experimental sample consisted of 99 orthodontic patients (43 from Boston, Mass, United States; 56 from Jerusalem, Israel) with at least one deciduous molar in infraocclusion greater than 1 mm vertical discrepancy, measured from the mesial marginal ridge of the first permanent molar. Panoramic radiographs and dental casts were used to determine the presence of other dental anomalies, including agenesis of permanent teeth, microdontia of maxillary lateral incisors, palatally displaced canines (PDC), and distal angulation of the mandibular second premolars (MnP2-DA). Comparative prevalence reference values were utilized and statistical testing was performed using the chi-square test ( $P < .05$ ) and odds ratio.

**Results:** The studied dental anomalies showed two to seven times greater prevalence in the infraocclusion samples, compared with reported prevalence in reference samples. In most cases, the infraoccluded deciduous molar exfoliated eventually and the underlying premolar erupted spontaneously. In some severe phenotypes (10%), the infraoccluded deciduous molar was extracted and space was regained to allow uncomplicated eruption of the associated premolar.

**Conclusion:** Statistically significant associations were observed between the presence of infraocclusion and the occurrence of tooth agenesis, microdontia of maxillary lateral incisors, PDC, and MnP2-DA. These associations support a hypothesis favoring shared causal genetic factors. Clinically, infraocclusion may be considered an early marker for the development of later appearing dental anomalies, such as tooth agenesis and PDC. (*Angle Orthod.* 2010;80:440–445.)

**KEY WORDS:** Infraocclusion; Dental anomalies; Tooth agenesis; Tooth, ectopic eruption; MnP2 distal angulation; Deciduous molars

## INTRODUCTION

Infraocclusion is a condition of tooth eruption insufficiency observed largely in human deciduous

molars but noted also in other teeth, including permanent molars. The infraoccluded tooth characteristically is positioned with its occlusal surface in a depressed position and at a measurable distance from the occlusal plane of its dental arch. The distance away from the occlusal plane can vary from a minor discrepancy of a millimeter to severity of a centimeter or more with the infraoccluded deciduous tooth sometimes found embedded in alveolar bone with its neighboring teeth tipped into its space. Some earlier common names for this dental anomaly have been retained deciduous tooth, tooth ankylosis, and submerged tooth. Now, infraocclusion, referring to the chief visual feature of the abnormality, has become the term of preference for this positional anomaly of teeth.

Early names for infraocclusion were usually tied to conjectures about its origins. Many etiologic factors have been proposed. In 1929, Bloch-Jorgensen<sup>1</sup> published seven severe cases of “retained deciduous

<sup>a</sup> Clinical Lecturer, Department of Orthodontics, Hebrew University–Hadassah School of Dental Medicine, Jerusalem, Israel.

<sup>b</sup> Clinical Professor, Department of Developmental Biology, Harvard School of Dental Medicine, Boston, Mass.

<sup>c</sup> Clinical Instructor, Department of Orthodontics, School of Dental Medicine, Tel-Aviv University, Israel Defense Forces, Tel-Aviv, Israel.

<sup>d</sup> Assistant Clinical Professor, Department of Developmental Biology, Harvard School of Dental Medicine, Boston, Mass.

Corresponding author: Dr Miriam Shalish, Department of Orthodontics, Hebrew University–Hadassah School of Dental Medicine, PO B 12272 Jerusalem, Israel 91120 (e-mail: mshalish@hadassah.org.il)

Accepted: September 2009. Submitted: June 2009.

© 2010 by The EH Angle Education and Research Foundation, Inc.

teeth” in one of the first radiographic studies of the infraocclusion condition. He concluded that a deciduous molar became deeply infraoccluded as a response to abnormally “checked eruption” of its succedaneous premolar. He postulated that an arrested premolar’s root would continue to grow, turning it more horizontally, thus forcing the overlying deciduous tooth to sink gingivally. By the 1950s, the histologic term *ankylosis* became attached to this clinical condition. Biederman<sup>2</sup> reasoned that during the process of shedding deciduous molars, a biologic mixup in the sequencing of periodontal ligament loss and deciduous tooth resorption might be the factor that triggers tooth ankylosis in some people. More recently, various unparsimonious hypotheses have been offered associating the occurrence of infraocclusion with other phenomena:

- Increased bone remodeling in the anterior mandible<sup>3</sup>
- Aberrant tongue posture<sup>4</sup>
- Tooth malformations at the embryonic neural crest stage<sup>5</sup>

Infraocclusion is often found as a familial condition. Many studies<sup>6–12</sup> have documented its occurrence in monozygotic twins and relatives in kindreds, adding Mendelian evidence to support a likely genetic mechanism underlying the expression of infraocclusion. Further corroboration of genetic etiologic factors comes from studies showing that infraocclusion is an abnormality frequently observed accompanying the presence of other dental anomalies.<sup>13–21</sup> Abnormal conditions such as tooth agenesis, microform teeth, delayed tooth development, palatally displaced canines (PDC), and mandibular second premolar distal angulation (MnP2-DA) have been found to occur together much more frequently than would be expected by chance. Combinations of these occurrences have been named dental anomaly patterns (abbreviated as DAP) by Peck<sup>22</sup> and form an important part of the problem list for 10% to 20% of orthodontic patients diagnosed with malocclusion.

This study was undertaken to examine relationships between infraocclusion and the occurrence of certain other dental anomalies in subjects selected for clear-cut infraocclusion of one or more deciduous molars. The null hypothesis was that subjects with infraocclusion of at least one deciduous molar do not demonstrate a statistically significantly increased prevalence rate of other studied dental anomalies.

## MATERIALS AND METHODS

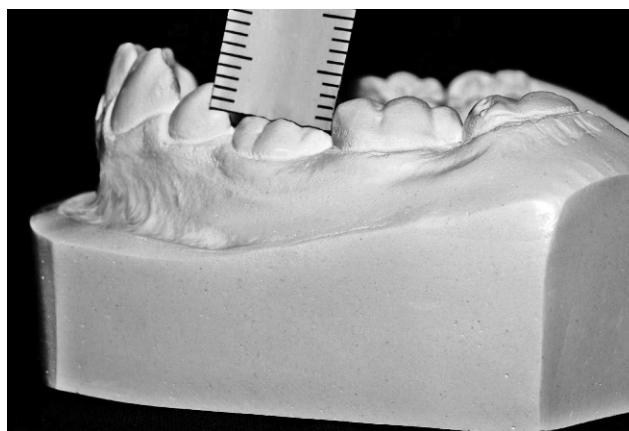
An experimental sample of 99 subjects with infraocclusion was collected, consisting of 43 orthodontic patients from Boston, Massachusetts, United States, and 56 patients from Jerusalem, Israel. The subjects

were selected retrospectively from pretreatment records of completed orthodontic patients in private offices in the United States and Israel, and from the orthodontic department in Hadassah hospital in Jerusalem. The 43 Boston subjects were orthodontic patients from the northeastern United States who self-identified as whites. The 56 Jerusalem subjects were orthodontic patients who self-identified as whites of European and Middle Eastern origin.

The criterion for inclusion in this sample was the presence of infraocclusion of a deciduous molar with more than 1 mm vertical discrepancy, as measured from the mesial marginal ridge of the closest permanent first molar, using pretreatment dental casts (Figure 1).

Panoramic radiographs and dental casts were studied for each subject to determine the presence of any of the following dental anomalies:

- Tooth agenesis** was determined by panoramic radiographic screening for absent permanent teeth, including third molars. Confirmation of the absence of third molars was provided by later radiographic examination at age 14 or older, a generally recognized critical age regarding third molar development.<sup>23</sup> Three categories of tooth agenesis were compiled: agenesis of teeth excluding third molars; agenesis of third molars (M3) only; and agenesis of premolars (P) only.
- Microdontia of maxillary lateral incisors** was identified by direct observation. This category of anomaly included peg-shaped, conical phenotype, defined by criteria established by Le Bot and Salmon,<sup>24</sup> and small maxillary lateral, defined in this study as one having a smaller maximum mesiodistal crown diameter than that of its opposing mandibular lateral incisor.



**Figure 1.** Mandibular dental cast showing measurement of infraocclusion of the mandibular left deciduous second molar (75). The millimeter ruler scale indicates 2 mm of infraocclusion, measured at the mesial marginal ridge of the neighboring permanent first molar.

—**Palatally displaced canine anomaly (PDC)** was diagnosed on the basis of initial radiographic records, if the subject was at least 10 years old at that time.<sup>25,26</sup> If younger at initial records, follow-up x-ray images were obtained later to confirm the presence of clear-cut PDC.

—**Mandibular second premolar distal angulation anomaly (MnP2-DA)** was defined as the mandibular second premolar forming a distal angle with the mandibular plane of less than 75 degrees. The choice of this threshold was based on results of previous studies introducing this positional anomaly.<sup>27–31</sup> The standardized method for measuring MnP2-DA described by Shalish et al<sup>27</sup> was employed.

Statistical analysis included descriptive statistics and the chi-square test for goodness of fit, which was used to compare the frequencies of dental anomalies in this sample with previously published reference values (except for MnP2-DA, for which an age- and sex-matched control sample was collected). The referenced comparative samples consisted of European or North American white subjects. Odds ratio was calculated at the 95% confidence interval.

To assess the clinical significance of infraocclusion, we examined the clinical diagnostic records of the 99 infraocclusion patients retrospectively to relate the types of orthodontic intervention with semiquantitative ratings of the severity of infraocclusion.

## RESULTS

Two geographically distinct samples totaling 99 orthodontic patients with infraocclusion of one or more deciduous molars were collected, having an age range of 8 to 15 years. Forty-three subjects were from Boston, Massachusetts, United States (24 females and 19 males), with a mean age of 10.8 years, and 56 subjects were from Jerusalem, Israel (30 females and 26 males), with a mean age of 10.1 years (Table 1). Female-to-male ratio was 6:5 in both samples.

For each sample, the severity of infraocclusion was divided semiquantitatively into three categories (mild, moderate, severe), determined by measuring the millimetric amount of submersion of the most infraoccluded tooth for each subject. Comparisons between the two geographic samples showed the following distribution: 30% (13) of the Boston sample and 38% (21) of the Jerusalem sample had mild infraocclusion (1–2 mm), and 49% (21) of the Boston sample and 38% (21) of the Jerusalem sample had moderate infraocclusion (>2 mm and <5 mm). Severe cases (>5 mm) were found in 21% (9) of the Boston sample and 25% (14) of the Jerusalem sample.

The rank order of infraocclusion occurrence according to location of affected deciduous molars was recorded.

**Table 1.** Comparison of Two Subsamples: Descriptive Statistics

Subsample	Total		Females		Males	
	N	Mean Age, y	n	Mean Age, y	n	Mean Age, y
Boston	43	10.8	24	10.5	19	11.2
Jerusalem	56	10.1	30	10.0	26	10.2

The mandibular deciduous second molar was the most frequently infraoccluded tooth with 99% (98 subjects) of subjects having this condition. All of the infraocclusion subjects except one showed infraocclusion of the mandibular deciduous second molar, while the other teeth showed infraocclusion only in some of these patients. The mandibular deciduous first molar was next most frequently infraoccluded tooth, with 44% (19) in the Boston sample and 32% (18) in the Jerusalem sample. The maxillary deciduous second molar was the third most frequent site at 33% (14) in the Boston sample and 16% (9) in the Jerusalem sample. The least frequent site for deciduous tooth infraocclusion was the maxillary deciduous first molar with 9% (4) in the Boston sample and 5% (3) in the Jerusalem sample.

The prevalence of other dental anomalies among the infraocclusion subjects is shown in Table 2. In both samples of patients with infraocclusion, a fourfold higher prevalence rate of agenesis of permanent teeth, excluding third molars, was seen compared with reference values in the general population. The prevalence rates of third molar agenesis and premolar agenesis were also increased in the samples. Small maxillary lateral incisors were five times more prevalent in the infraocclusion samples compared with the reference values. PDC anomaly was seen approximately seven times more frequently in the infraocclusion subjects than in the general population. MnP2-DA anomaly averaged over three times the relative frequency noted in the control sample.

To ascertain the reasonableness of combining the two geographically distinct infraocclusion samples for statistical testing, the odds ratio was employed as a measure of the strength of the relationship between the two samples, regarding each anomaly (Table 3). Because the value of the ratio is close to 1 or less, the Boston and Jerusalem samples may be considered not significantly different in prevalence of each of the anomalies studied (ie, each anomaly should be equally likely to appear in the two samples). Table 3 compares the prevalence of each anomaly in each sample with that in the other sample, using odds ratio. In all cases, the values are within the 95% confidence interval. For the first five anomalies (tooth agenesis, small MxI2, and PDC) the calculated odds ratio was close to 1, showing that these anomalies are of rather equal likelihood to appear in both samples. The odds ratio in

**Table 2.** Prevalence Rates of the Six Studied Dental Anomalies, With Comparisons of Data From the Two Infraocclusion Samples With General Population Reference Values

Dental Anomaly (DA)	n = 43 (Boston)	n = 56 (Jerusalem)	Reference Values
Agenesis (excluding M3)	20.90% (9/43)	21.40% (12/56)	5% (53/1064) (Grahnén, <sup>32</sup> 1956)
Agenesis of M3	41.90% (18/43)	31.60% (6/19)	20.7% (427/2061) (Bredy, <sup>33</sup> 1991)
Agenesis of P2	18.60% (8/43)	21.40% (12/56)	5.8% (58/1000) (Baccetti, <sup>18</sup> 1998)
Small MxI2	25.60% (11/43)	21% (4/19)	4.7% (47/1000) (Baccetti, <sup>18</sup> 1998)
PDC	11.60% (5/43)	12.50% (7/56)	1.7% (25/1450) (Dachi, <sup>34</sup> 1961)
Distal angulation of MnP2 (MnP2-DA)	34.90% (15/43)	55.30% (31/56)	13.1% (13/99) (control sample)

M3=Third Molar  
P2=Second Premolar  
MxI2=Maxillary Lateral Incisor  
PDC=Palatally Displaced Canine  
MnP2=Mandibular Second Premolar.

the case of MnP2 distal angulation anomaly deviated from one considerably. Thus, MnP2-DA was evaluated for each geographic sample separately. The two samples were combined for an n = 99 only for the first five dental anomaly categories studied.

The prevalence of five dental anomalies occurring in the infraocclusion combined sample compared with general population occurrence is shown in Table 4. The observed greater prevalence of anomalies in subjects with infraocclusion compared with published reference values was significant statistically at the *P* < .01 level.

For the MnP2 distal angulation (MnP2-DA) anomaly, the Boston and Jerusalem samples separately were compared (Table 5) with an age- and sex-matched control sample. Findings showed this anomaly to have a statistically significant greater occurrence in both groups of subjects with infraocclusion, when compared with the control sample.

Comparison of prevalence of the six dental anomalies in the Boston and Jerusalem infraocclusion samples vs reference values is summarized graphically in Figure 2.

The clinical significance of infraocclusion was evaluated on the basis of the results of this investigation. In 89 of 99 patients (90%), the infraoccluded deciduous molar exfoliated naturally, and its successor, the permanent premolar, erupted spontaneously in its place. In about half of the subjects having the “severe” phenotype (10 of 99, or 10% of the combined sample), space was regained, and this was followed by extraction of the infraoccluded deciduous molar to allow uncomplicated eruption of the permanent premolar.

**Table 3.** Comparison of Prevalence Rates of the Six Studied Dental Anomalies Between the Two Infraocclusion Samples Using Odds Ratio

Dental Anomaly (DA)	n = 43 (Boston)	n = 56 (Jerusalem)	Odds Ratio (95% Confidence Interval)
Tooth agenesis (excluding M3)	20.90% (9/43)	21.40% (12/56)	1.03 (0.38–2.72)
Agenesis of M3	41.90% (18/43)	31.60% (6/19)	0.64 (0.20–2.0)
Agenesis of P2	18.60% (8/43)	21.40% (12/56)	1.19 (0.44–3.23)
Small MxI2	25.60% (11/43)	21% (4/19)	0.77 (0.21–2.84)
PDC	11.60% (5/43)	12.50% (7/56)	1.08 (0.31–3.69)
Distal angulation of MnP2 (MnP2-DA)	34.90% (15/43)	55.30% (31/56)	2.31 (1.02–5.25)

M3=Third Molar  
P2=Second Premolar  
MxI2=Maxillary Lateral Incisor  
PDC=Palatally Displaced Canine  
MnP2=Mandibular Second Premolar.

**DISCUSSION**

This study was undertaken to test further whether infraocclusion of deciduous molars was another component of dental anomaly patterns, groups of interrelated, concomitant dental abnormalities that likely have shared genetic origins. In selecting discrete anomalies for study, we included four categories that previously have been shown to be directly associated with infraocclusion to test whether our infraocclusion sample indeed manifested the same previously noted associations: any tooth agenesis (except M3) and the premolar agenesis subgroup,<sup>15–21</sup> PDC,<sup>18</sup> and microdontia of maxillary lateral incisors.<sup>18</sup> More significantly, two dental anoma-

**Table 4.** Comparison of Prevalence Rates of Dental Anomalies in the Infraocclusion Combined Sample and in the General Population, Using Chi-Square Test (n = 99)

Dental Anomaly (DA)	Infraocclusion Prevalence Rate	Reference Sample	Chi-Square (P Value)
Tooth agenesis (excluding M3)	21.20% (21/99)	5% (53/1064) (Grahnén, <sup>32</sup> 1956)	54.7 (<.01)
Agenesis of M3	38.70% (24/62)	20.7% (427/2061) (Bredy, <sup>33</sup> 1991)	12.2 (<.01)
Agenesis of P2	20.20% (20/99)	5.8% (58/1000) (Baccetti, <sup>18</sup> 1998)	37.6 (<.01)
Small MxI2	24.20% (15/62)	4.7% (47/1000) (Baccetti, <sup>18</sup> 1998)	52.6 (<.01)
PDC	12.10% (12/99)	1.7% (25/1450) (Dachi, <sup>34</sup> 1961)	64.3 (<.01)

M3=Third Molar  
P2=Second Premolar  
MxI2=Maxillary Lateral Incisor  
PDC=Palatally Displaced Canine.

**Table 5.** Comparison of Prevalence Rates of MnP2 Distal Angulation (MnP2-DA) Anomaly in the Infraocclusion Samples and in a Control Sample Using the Chi-Square Test

	n = 43 (Boston)	n = 56 (Jerusalem)	Reference Values (control sample)
Prevalence rate	34.9% (15/43)	55.3% (31/56)	13.1% (13/99)
Chi-square	18.2	88.8	
P value	<.01	<.01	

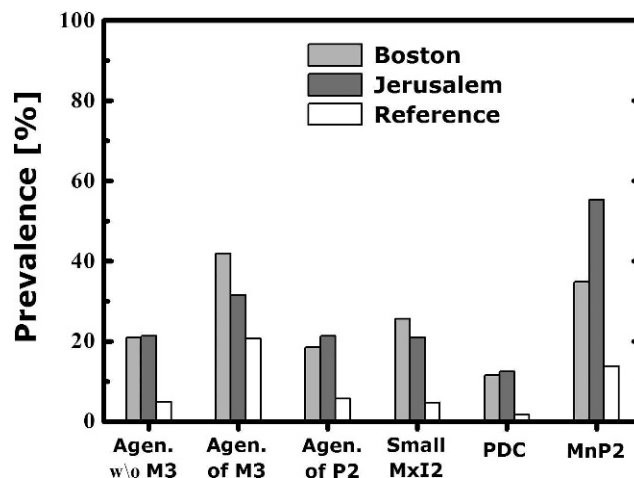
lies previously untested relative to concomitant occurrence with infraocclusion were featured in this study: agenesis of M3 and MnP2 distal angulation (MnP2-DA).

The results showed a clear and statistically significant increase in prevalence of the four previously reported and the two newly added anomaly categories among subjects with infraocclusion, compared with their reported prevalence in the general population. The null hypothesis was thus rejected.

The observed association among this group of dental anomalies unrelated mechanically or by anatomic proximity suggests a common biologic causality such as genetic mechanisms. If each of these anomalies is induced through genetic mutation, then each of them should be expected to show familial tendency. Indeed, infraocclusion, agenesis, PDC, and small maxillary lateral incisors have all been reported to manifest familial tendencies. While familial tendency points to genetic control, the association among the different anomalies goes one step further to suggest a *common* genetic origin.

The relative frequency rank of occurrence of infraoccluded deciduous molars according to location in this study was identical to the rank order found in two samples by Biederman<sup>35</sup> and in children from 9 to 12 years studied by Kuroi.<sup>8</sup> However, the broader age range of the samples in this study may have affected some results. For example, the older subjects (>11 years of age) may have already exfoliated some deciduous first molars, creating an age-based bias in relative overrepresentation of deciduous second molars in the Boston and Jerusalem samples.

From a clinical viewpoint, when an infraoccluded deciduous molar is observed in a child, a search for associated problems should be undertaken. Anomalous dental conditions should no longer be interpreted simply as isolated local phenomena. For example, in examining an 8-year-old with infraoccluded mandibular deciduous molars, we should contemplate a missing tooth somewhere, another deciduous molar beginning to infraocclude, an unerupted maxillary canine becoming ectopic palatally, and an eventual nonextraction treatment due to naturally small teeth. New knowledge of these significant relationships in dental develop-



**Figure 2.** Comparison of prevalence rates of studied dental anomalies in Boston and Jerusalem infraocclusion samples and reference values.

mental biology should make clinicians feel significantly more powerful in their diagnostic acumen.

## CONCLUSIONS

- Statistically significant associations were observed between the presence of infraocclusion and the occurrence of tooth agenesis, microdontia of maxillary lateral incisors, PDC, and MnP2-DA.
- These associations support infraocclusion of deciduous molars as another component of dental anomaly patterns (DAP), groups of interrelated, concomitant dental abnormalities that likely have shared genetic origins.
- Clinically, infraocclusion is a transitory anomaly, usually leaving no permanent impact. Only in the minority of extremely severe cases (10%) are deciduous tooth extraction and orthodontic space regaining indicated. Infraocclusion may be considered an early marker for the development of later appearing dental anomalies, such as tooth agenesis and PDC.

## REFERENCES

1. Bloch-Jorgensen K. Retained deciduous molars. *Dent Cosmos*. 1929;71:1186–1188.
2. Biederman W. Etiology and treatment of tooth ankylosis. *Am J Orthod*. 1962;48:670–684.
3. Leonardi M, Armi P, Baccetti T, Franchi L, Caltabiano M. Mandibular growth in subjects with infraoccluded deciduous molars: a superimposition study. *Angle Orthod*. 2005;75:927.
4. Mew J. Re: Infraocclusion and the tongue [letter]. *Angle Orthod*. 2006;76:following 541.
5. Kjaer I, Fink-Jensen M, Andreasen JO. Classification and sequelae of arrested eruption of primary molars. *Int J Paediatr Dent*. 2008;18:11–17.
6. Via NF. Submerged deciduous molars: familial tendencies. *J Am Dent Assoc*. 1964;69:127–129.

7. Stewart RE, Hansen RW. Ankylosis and partial anodontia in twins. *J Calif Dent Assoc.* 1974;2:50–52.
8. Kuroi J. Infraocclusion of primary molars: an epidemiologic and familial study. *Community Dent Oral Epidemiol.* 1981;9:94–102.
9. Helpin ML, Duncan WK. Ankylosis in monozygotic twins. *ASDC J Dent Child.* 1986;53:135–139.
10. Pytlik W, Alfter G. Impairment of tooth eruption: pathogenetic aspects. *J Orofac Orthop.* 1996;57:238–245.
11. Dewhurst SN, Harris JC, Bedi R. Infraocclusion of primary molars in monozygotic twins: report of two cases. *Int J Paediatr Dent.* 1997;7:25–30.
12. Cozza P, Gatto R, Ballanti F, De Toffol L, Mucedero M. Case report: severe infraocclusion ankylosis occurring in siblings. *Eur J Paediatr Dent.* 2004;5:174–178.
13. Hoffmeister H. Tongue pressure or inherited susceptibility as a primary cause of infraocclusion or impaction of deciduous molars? [in German]. *Fortschr Kieferorthop.* 1983;44:316–325.
14. Kuroi J. Infraocclusion of primary molars: an epidemiological, familial, longitudinal clinical and histological study. *Swed Dent J Suppl.* 1984;21:1–67.
15. Lai PY, Seow WK. A controlled study of the association of various dental anomalies with hypodontia of permanent teeth. *Pediatr Dent.* 1989;11:291–296.
16. Bjerklin K, Kuroi J, Valentin J. Ectopic eruption of maxillary first permanent molars and association with other tooth and developmental disturbances. *Eur J Orthod.* 1992;14:369–375.
17. Baccetti T, Tollaro I. Infraocclusion of primary molars as a dental anomaly of genetic origin. In: Radlanski RJ, Renz H, eds. *Proceedings of the 10th International Symposium on Dental Morphology.* Berlin: “M” Marketing-Services; 1995:428–432.
18. Baccetti T. A controlled study of associated dental anomalies. *Angle Orthod.* 1998;68:267–274.
19. Baccetti T. Tooth anomalies associated with failure of eruption of first and second permanent molars. *Am J Orthod Dentofacial Orthop.* 2000;118:608–610.
20. Sidhu HK, Ali A. Hypodontia, ankylosis and infraocclusion: report of a case restored with a fibre-reinforced ceromeric bridge. *Br Dent J.* 2001;191:613–616.
21. Garib DG, Peck S, Gomes SC. Increased occurrence of dental anomalies associated with second-premolar agenesis. *Angle Orthod.* 2009;79:436–441.
22. Peck S. Dental anomaly patterns (DAP): a new way to look at malocclusion. *Angle Orthod.* 2009;79:1015–1016.
23. Garn SM, Lewis AB. The relationship between third molar agenesis and reduction in tooth number. *Angle Orthod.* 1962;32:14–18.
24. Le Bot P, Salmon D. Congenital defects of the upper lateral incisors (ULI): condition and measurements of the other teeth, measurements of the superior arch, head and face. *Am J Phys Anthropol.* 1977;46:231–244.
25. McSherry P, Richardson A. Ectopic eruption of the maxillary canine quantified in three dimensions on cephalometric radiographs between the ages of 5 and 15 years. *Eur J Orthod.* 1999;21:41–48.
26. Peck S, Peck L, Kataja M. Prevalence of tooth agenesis and peg-shaped maxillary lateral incisor associated with palatally displaced canine (PDC) anomaly. *Am J Orthod Dentofacial Orthop.* 1996;110:441–443.
27. Shalish M, Peck S, Wasserstein A, Peck L. Malposition of unerupted mandibular second premolar associated with agenesis of its antimere. *Am J Orthod Dentofacial Orthop.* 2002;121:53–56.
28. Wasserstein A, Shalish M. Adequacy of mandibular premolar position despite early loss of its deciduous molar. *ASDC J Dent Child.* 2002;69, 254–258, 233–234.
29. Wasserstein A, Brezniak N, Shalish M, Heller M, Rakocz M. Angular changes and their rates in concurrence to developmental stages of the mandibular second premolar. *Angle Orthod.* 2004;74:332–336.
30. Shalish M, Will LA, Shustermann S. Malposition of unerupted mandibular second premolar in children with cleft lip and palate. *Angle Orthod.* 2007;77:1062–1066.
31. Shalish M, Chaushu S, Wasserstein A. Malposition of unerupted mandibular second premolar in children with palatally displaced canines. *Angle Orthod.* 2009;79:796–799.
32. Grahén H. Hypodontia in the permanent dentition: a clinical and genetical study. *Odontol Rev.* 1956;(suppl 3):1–100.
33. Bredy E, Erbring C, Hübenthal B. The incidence of hypodontia with the presence and absence of wisdom teeth. [in German]. *Dtsch Zahn Mund Kieferheilkd Zentralbl.* 1991;79:357–363.
34. Dachi SF, Howell FV. A survey of 3,874 routine full-month radiographs. II. A study of impacted teeth. *Oral Surg Oral Med Oral Pathol.* 1961;14:1165–1169.
35. Biederman W. The problem of the ankylosed tooth. *Dent Clin North Am.* 1968;July:409–424.